



Inkunabelraum

Soe 63



Mißbildungen von Kack
mit Antem gegessen



WIEN,

Lieferung: I.

aus der Sammlung
Seiner Kaiserlichen Hoheit des durchlauchtigsten
Erzherzogs Carl von Oesterreich.

der ITALIENISCHEN Schule

BERÜHMTER ALTER MEISTER

ORIGINAL HANDBUCH

VON

LITTHOGRAPHIRTE COPIE

Delineatio

Tumoris permagni in femore
popliteque dextro

foeminae Dozheimensis

Prope Wiesbaden


quem extirpavit

Perill. Weidmann

1789 die 22^{da} Jun.

Delineavit

Dr. Neuf. Med. Cand.



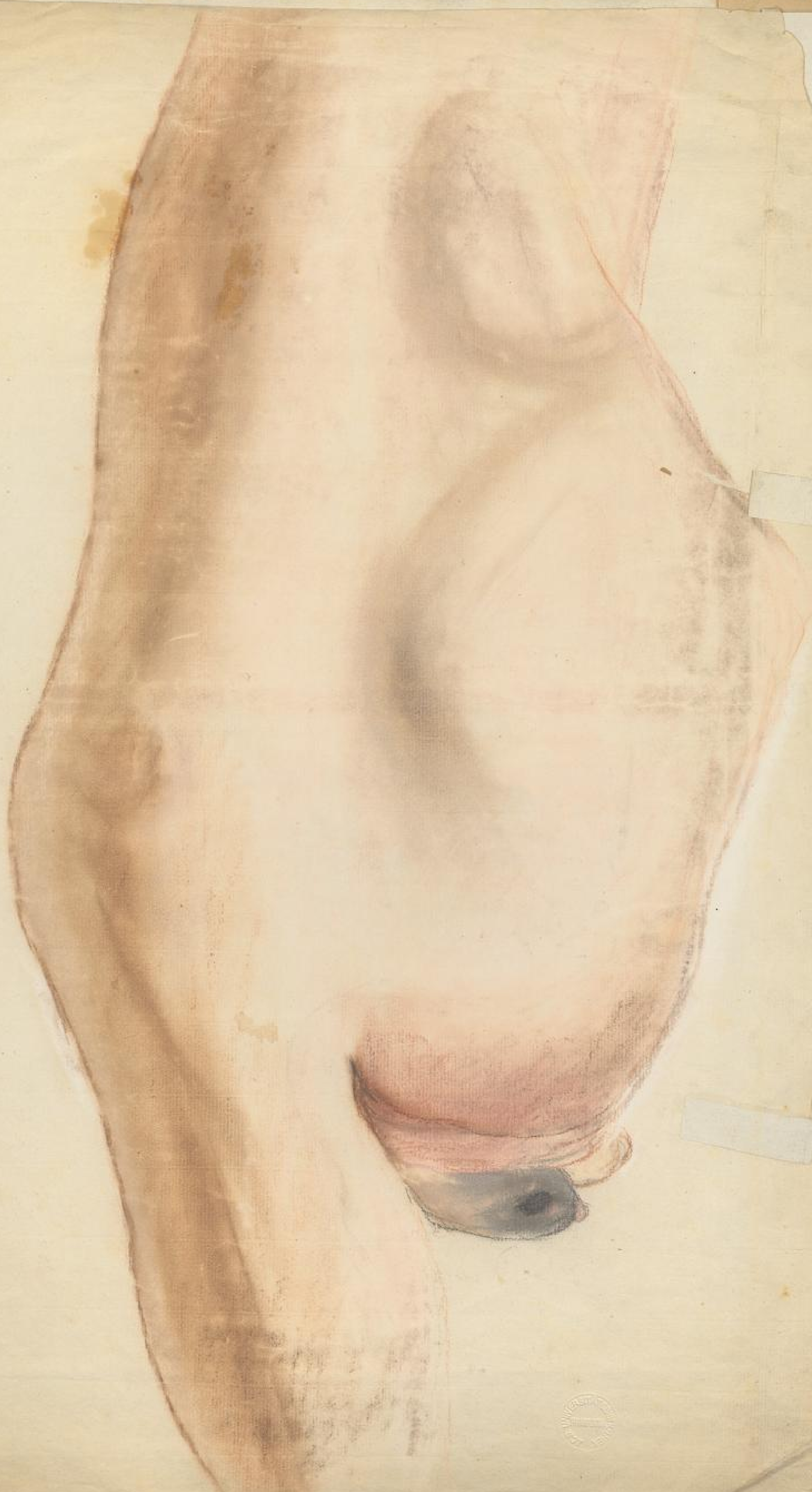h.
higste

STEN

TUNO

OPTI





ste

HE

NO

PT



Wissenschaftliche Prolegomena
von Koch 1823

Utricularia ovata Linn.

18. 10. 1823

Senckenberg


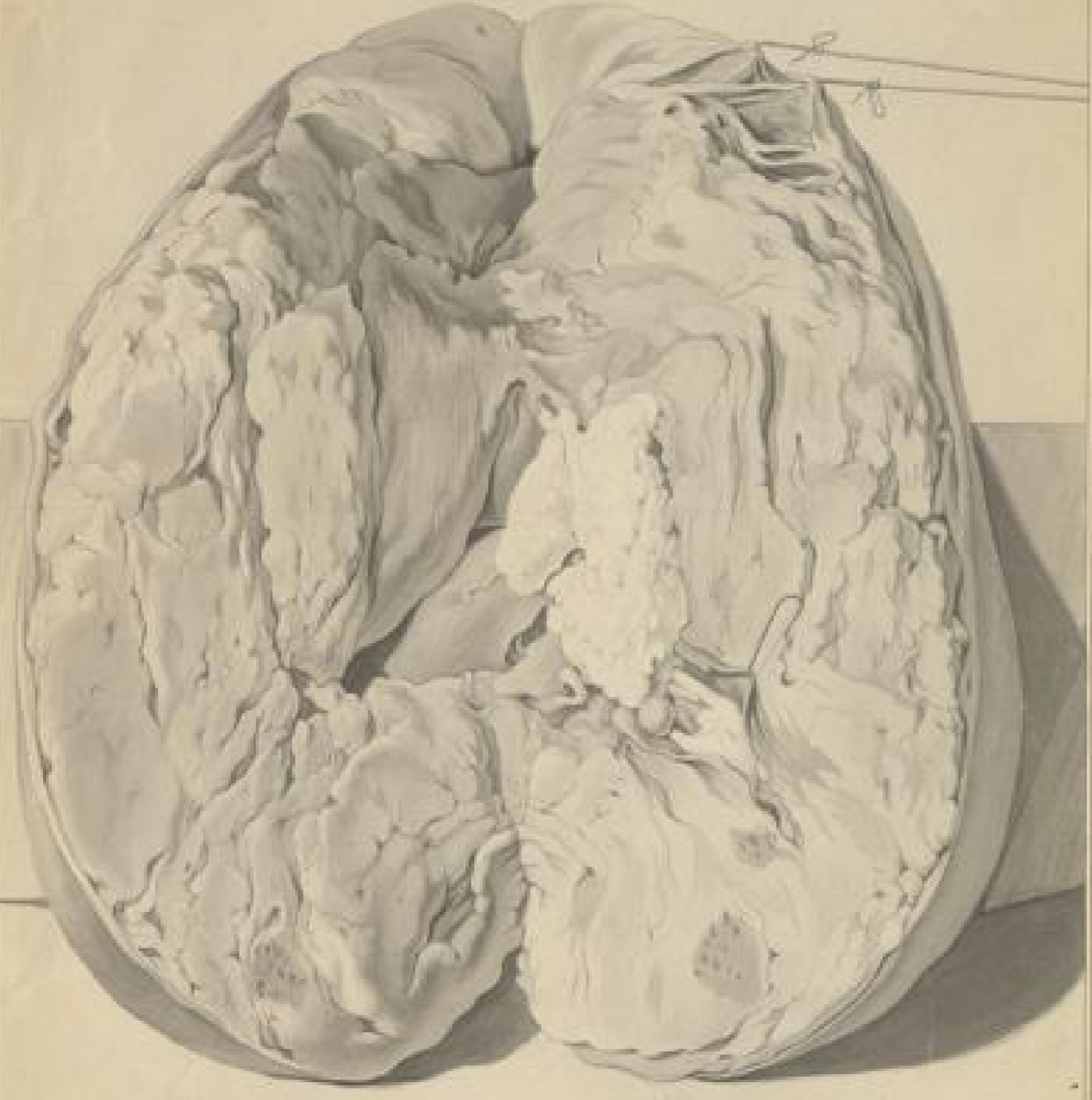
ste

ER

NO

PT





ste

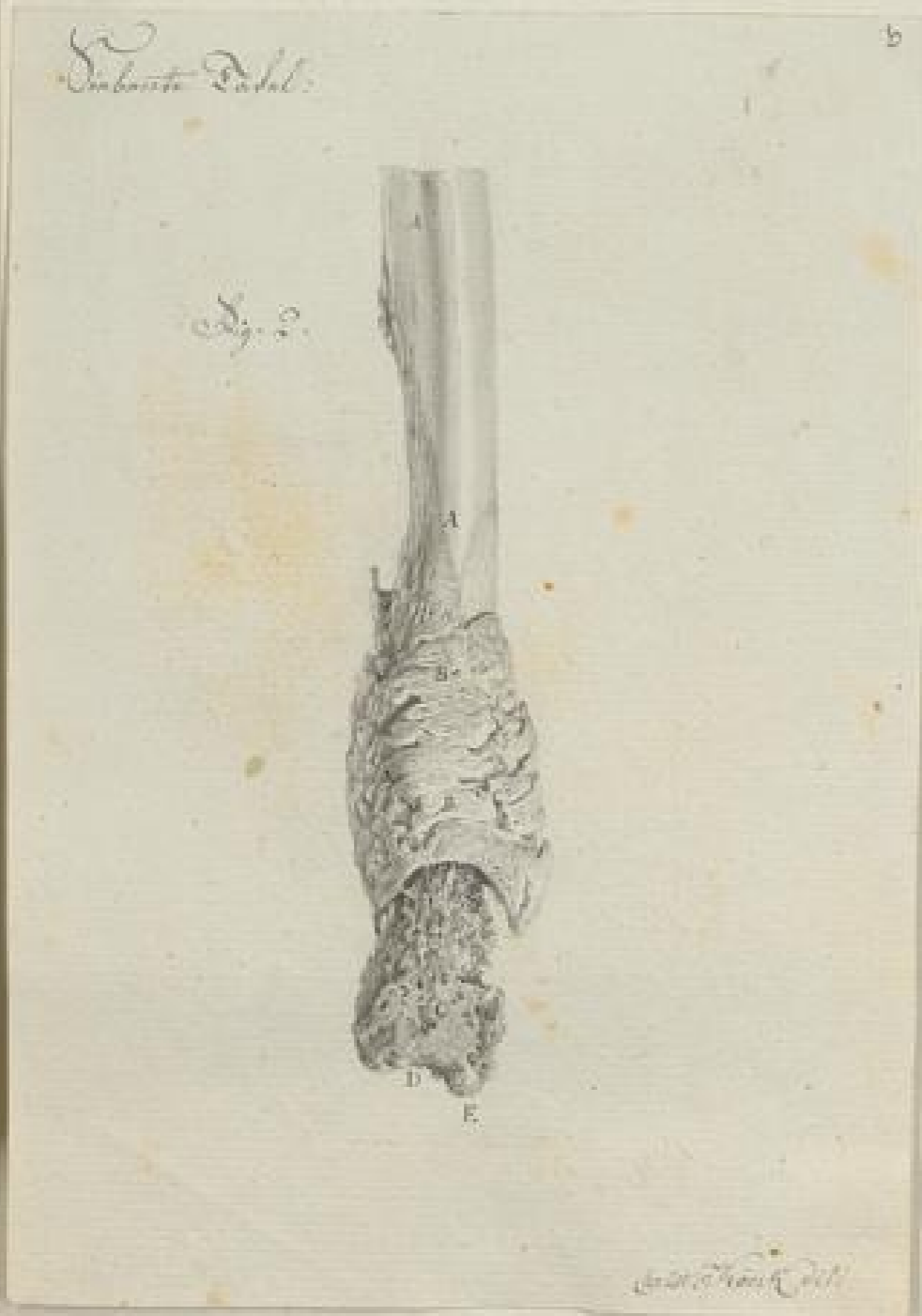
RE

ON

TO

67

9
25




ste

FE

ON

IT





Stomachus gastricus dissectio externa

J. G. G. del.

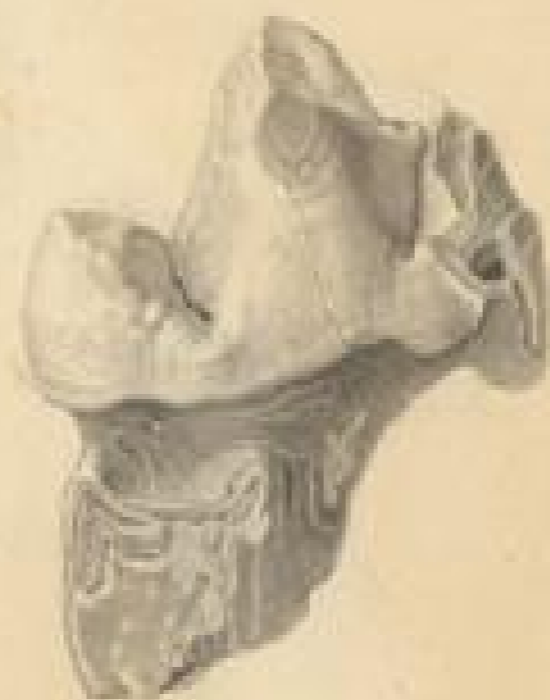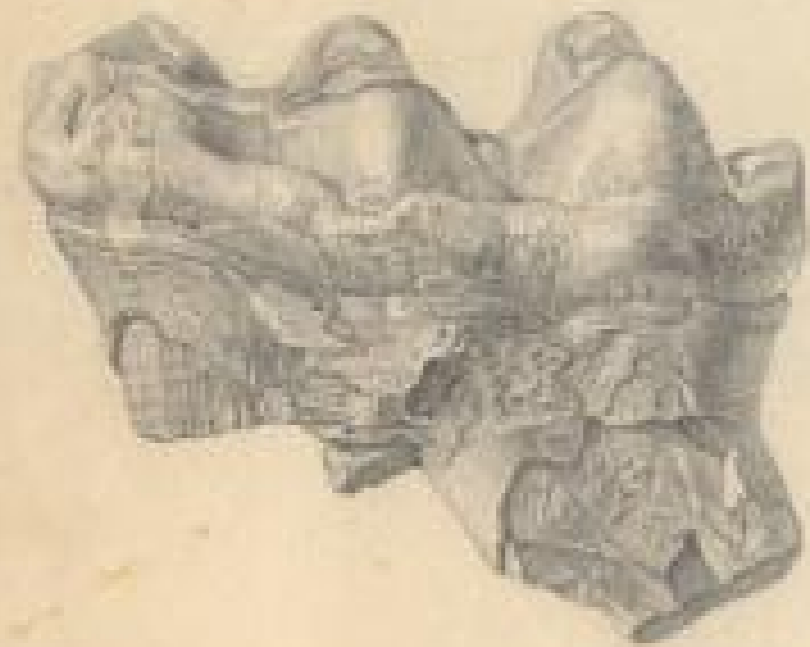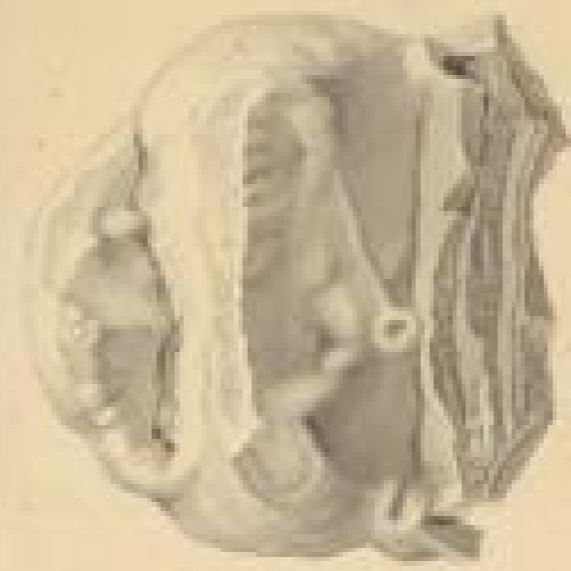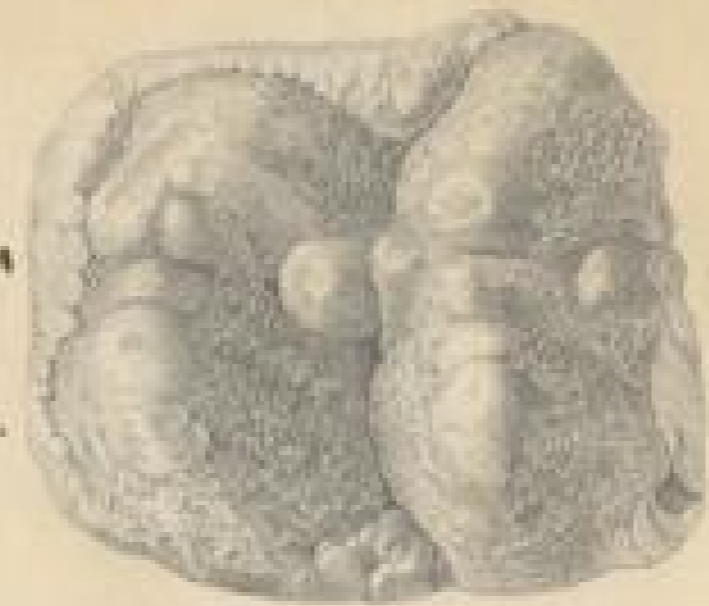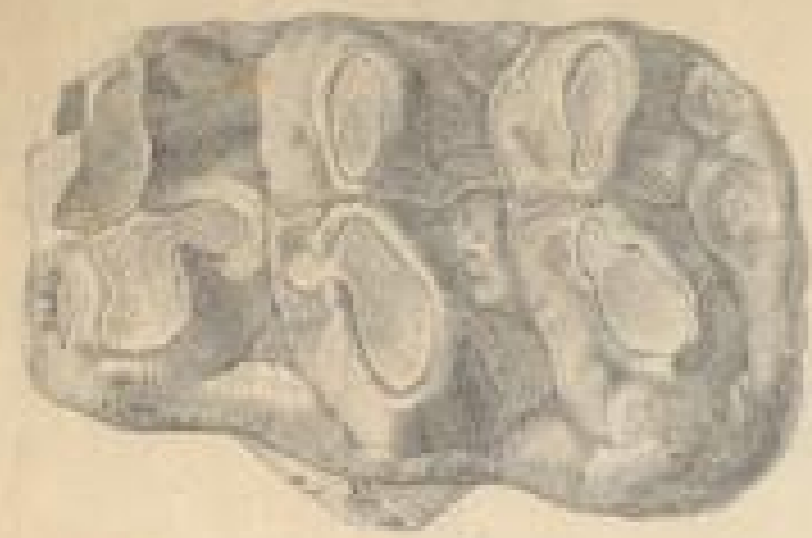
te

19

ER

ON

IT



Platystrophia

te

19

RE

ON

IT



60

I. Tafel.

Fig. 1.

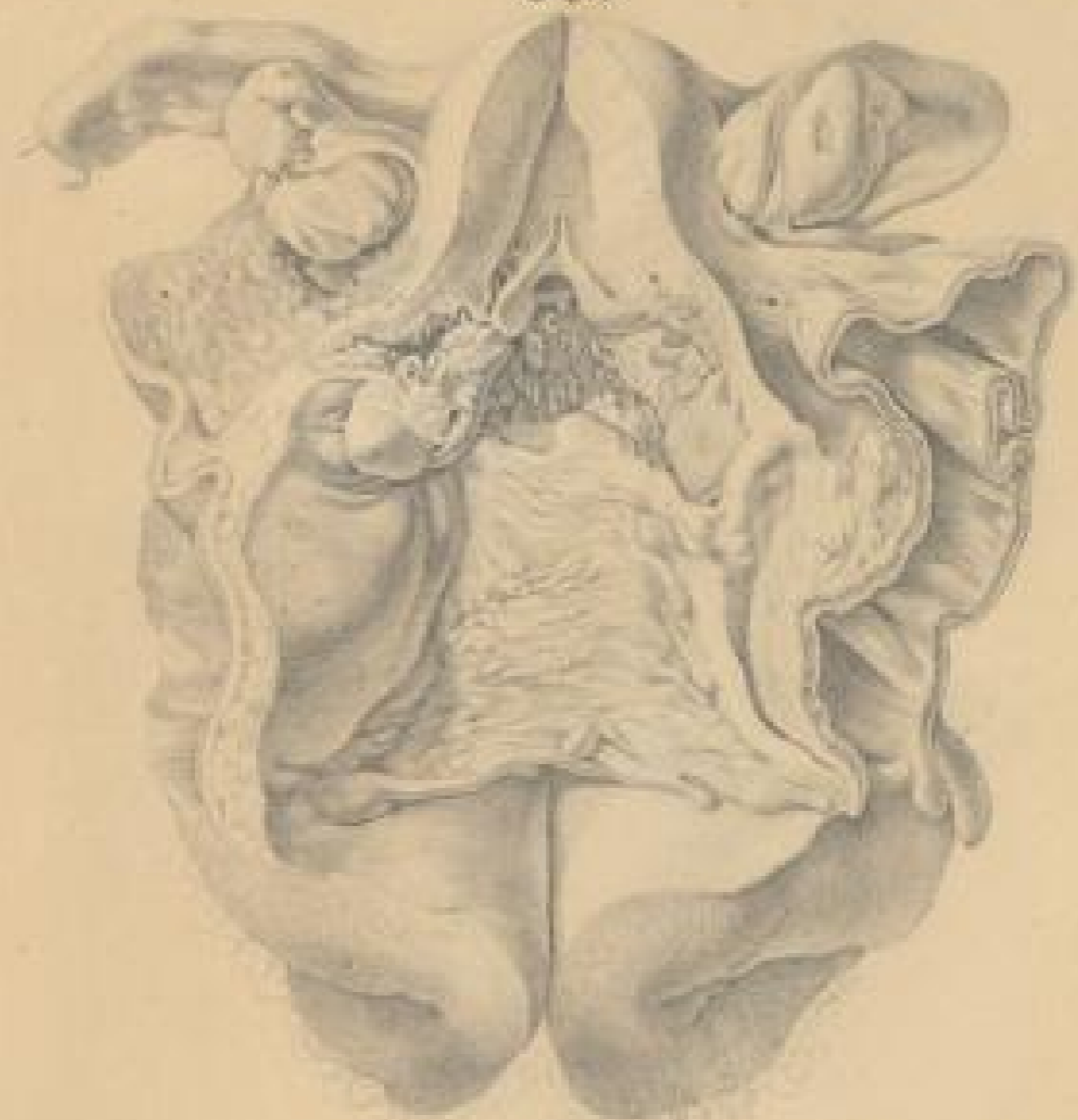

Fig. 2.



I. Tafel .

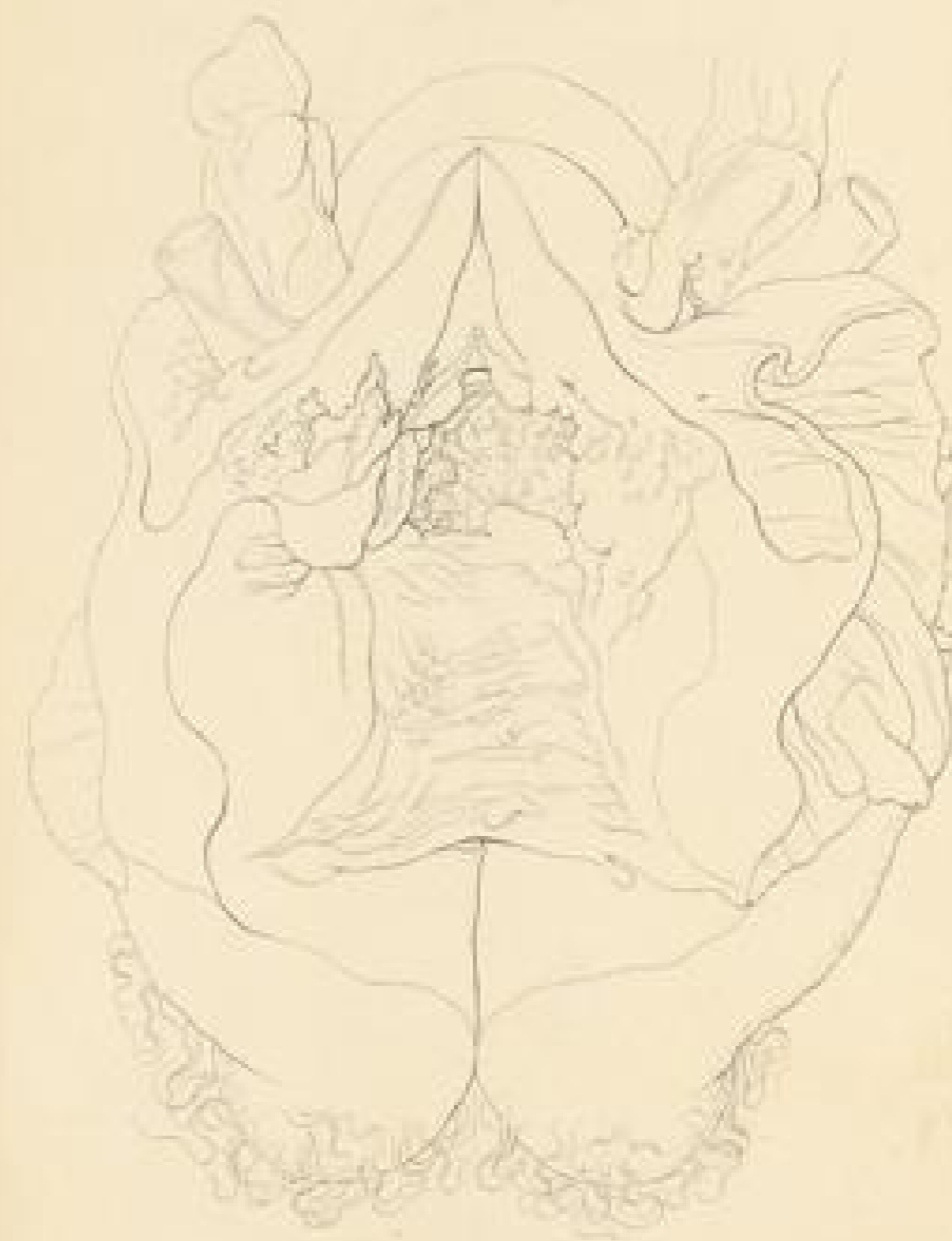

Fig. 3.



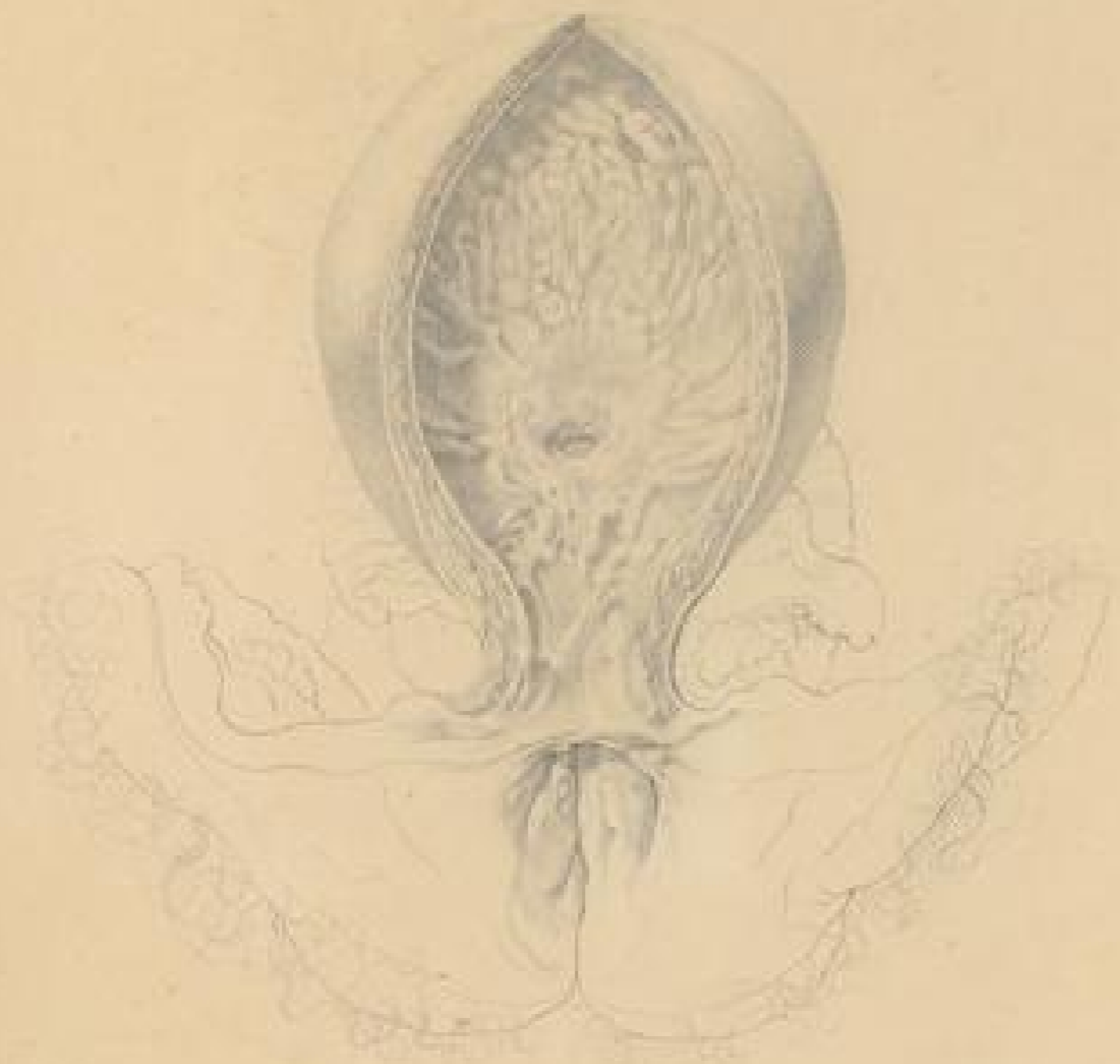te

LE

ON

IT

II. Tafel.



Quart. Tafel 2.

10

III. Tafel.



Quart. Tafel 2.

11

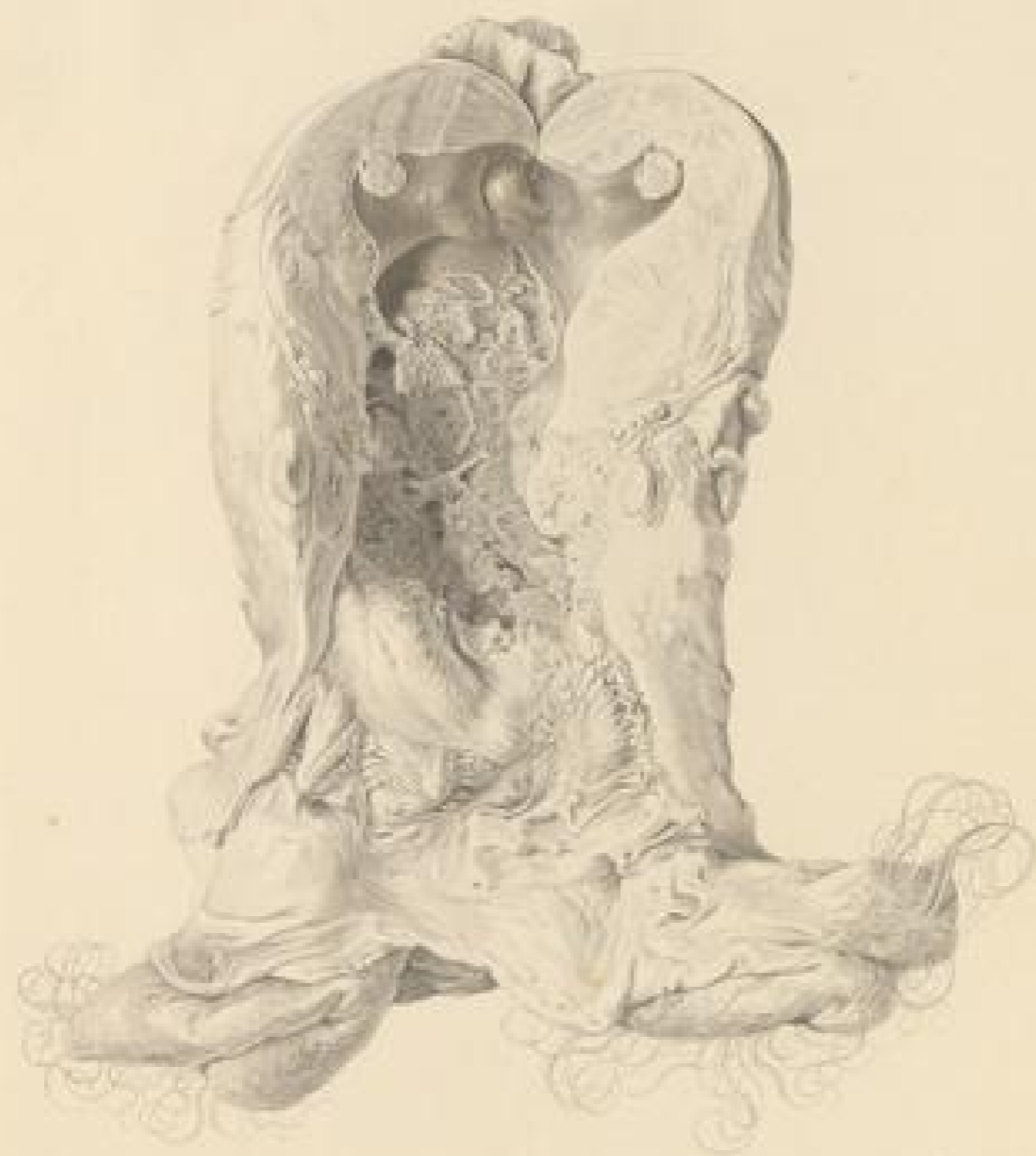te

HE

ON

IT

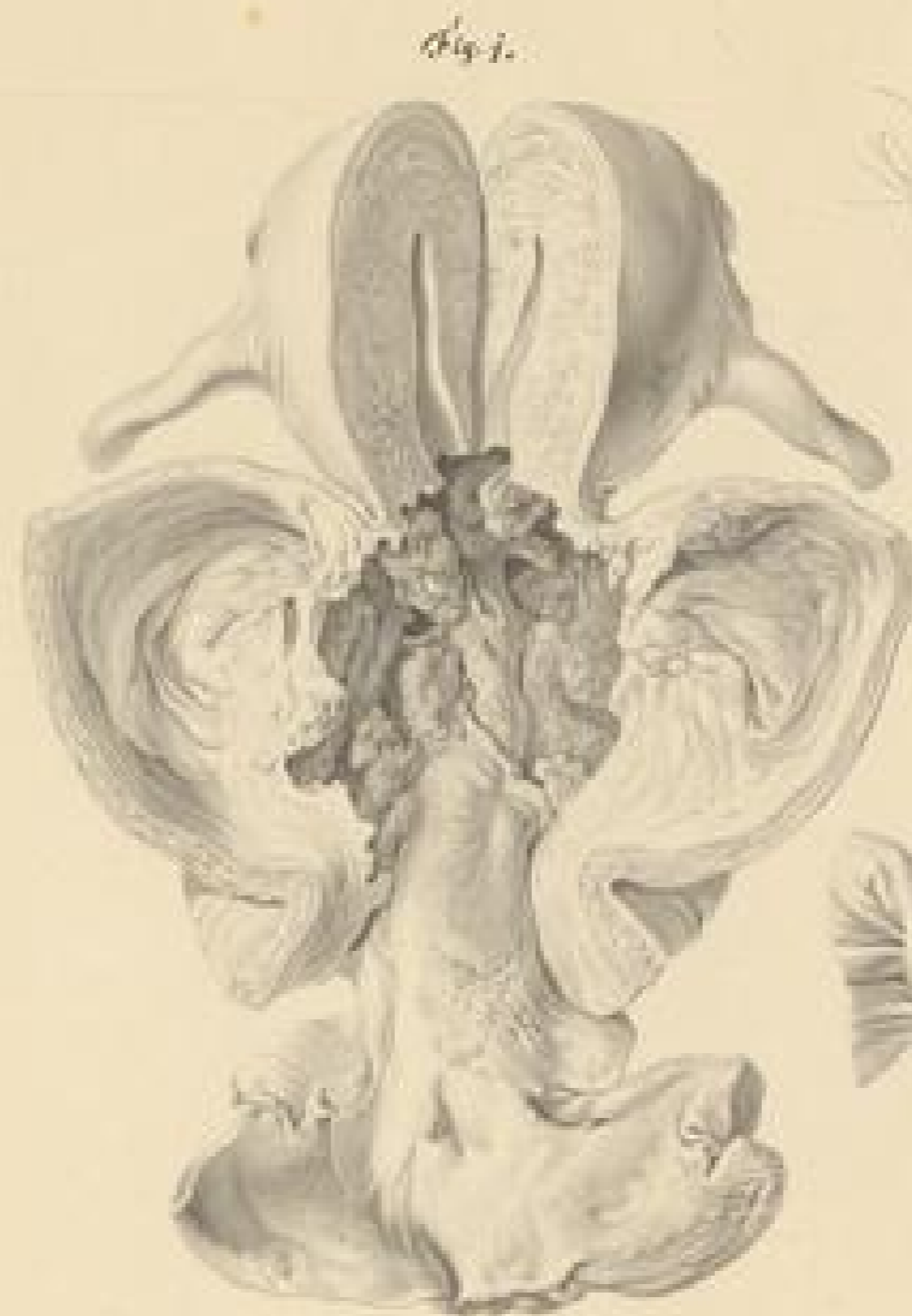IV. Tafel.



Handwritten text, possibly a signature or reference number.

Small handwritten mark or signature.

V. Tafel.



Handwritten text, possibly a signature or reference number.

Fig. 2.

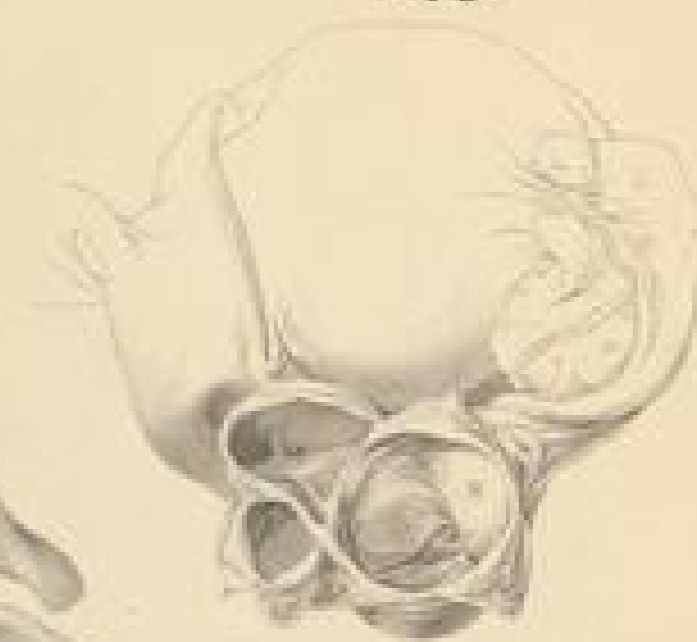
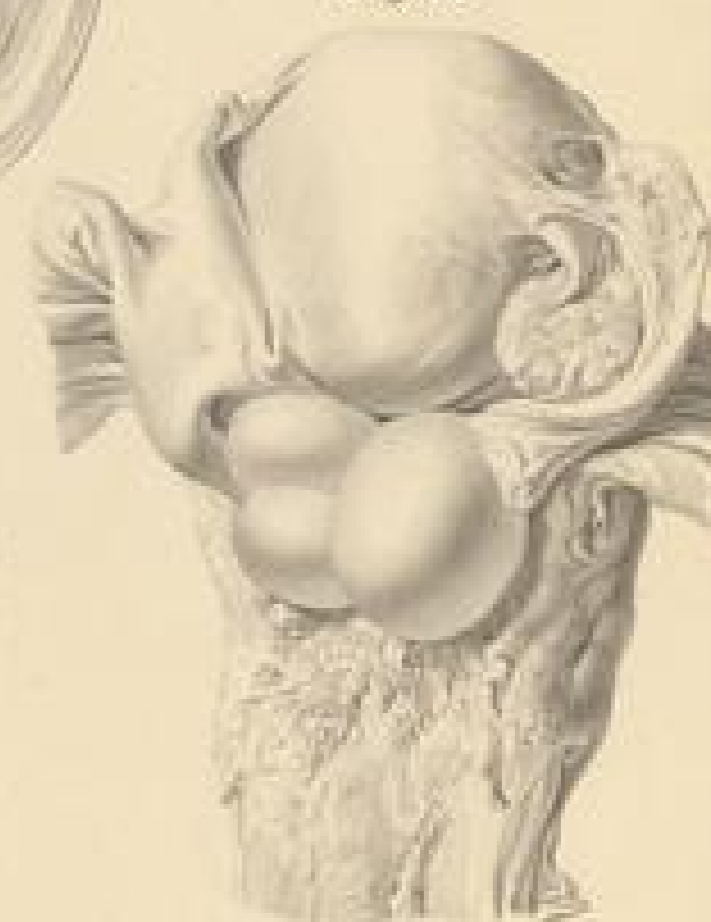
Fig. 3.



Small handwritten mark or signature.

te

RE

ON

IT



Mc



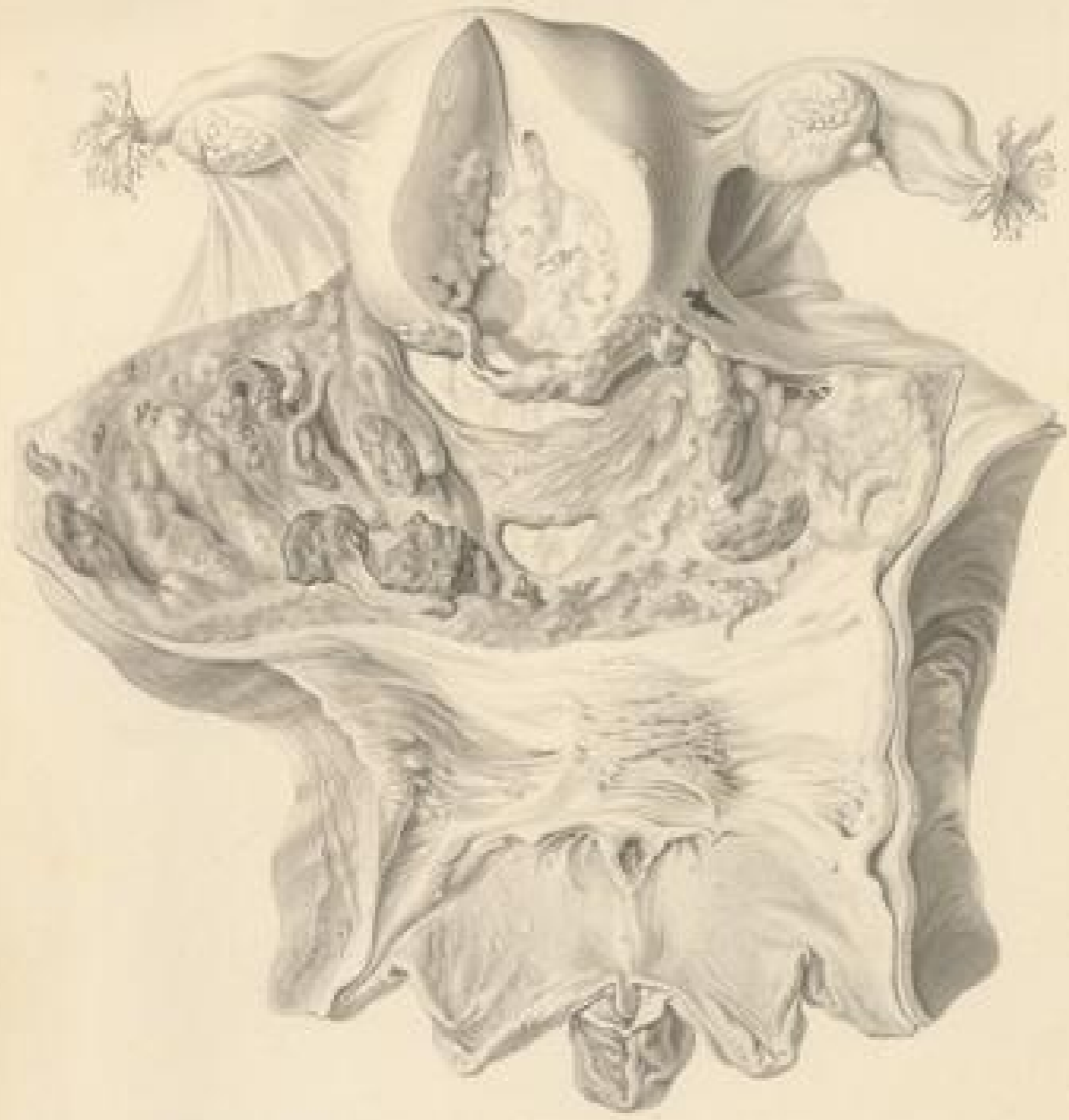te

EE

ON

IT

VI. Tafel.



Handwritten text, possibly a signature or reference number.



Fig. 1. Fetus humanus.

Handwritten text, possibly a signature or reference number.



Fig. 2. Fetus humanus.

Handwritten text, possibly a signature or reference number.

81

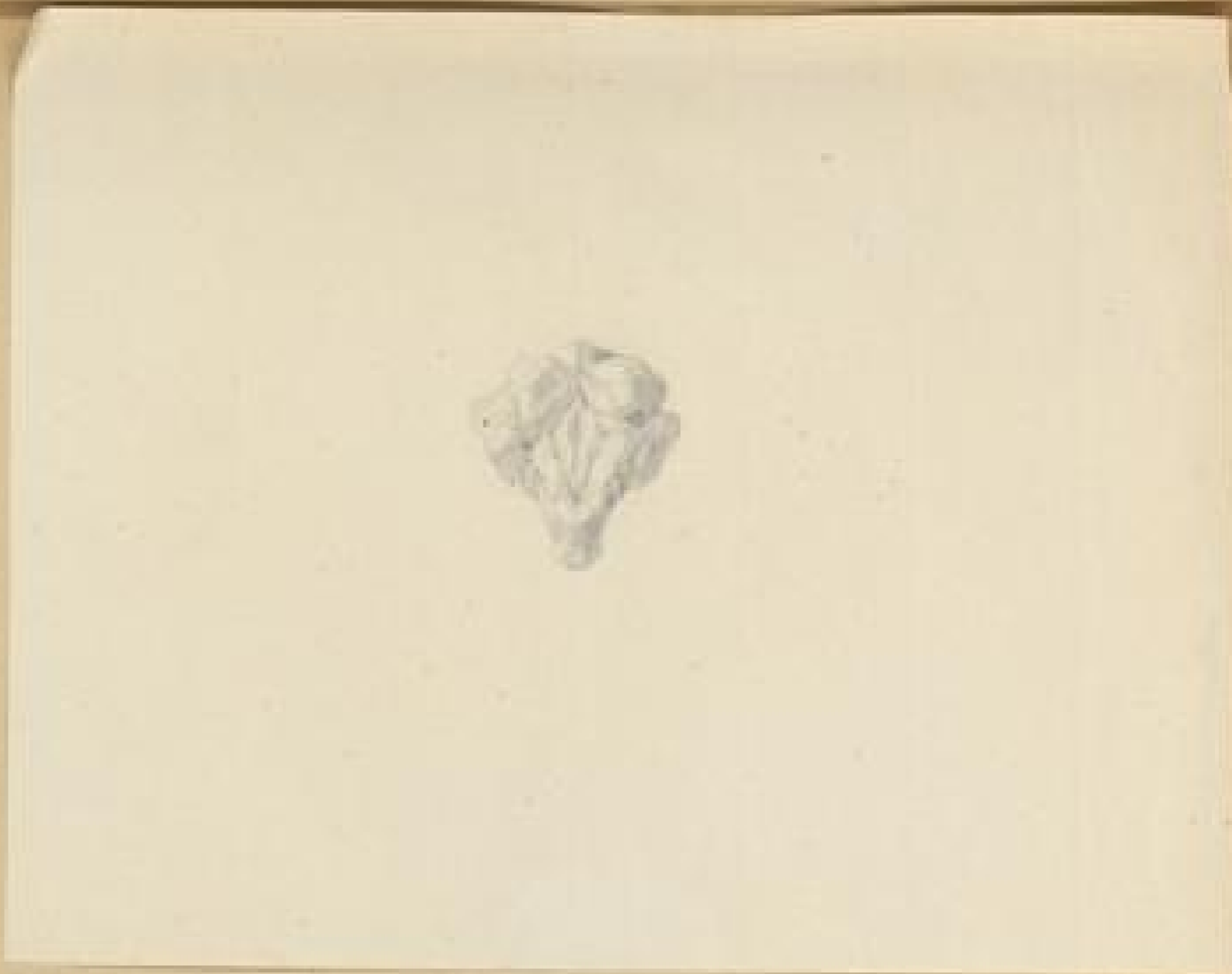ER

DI

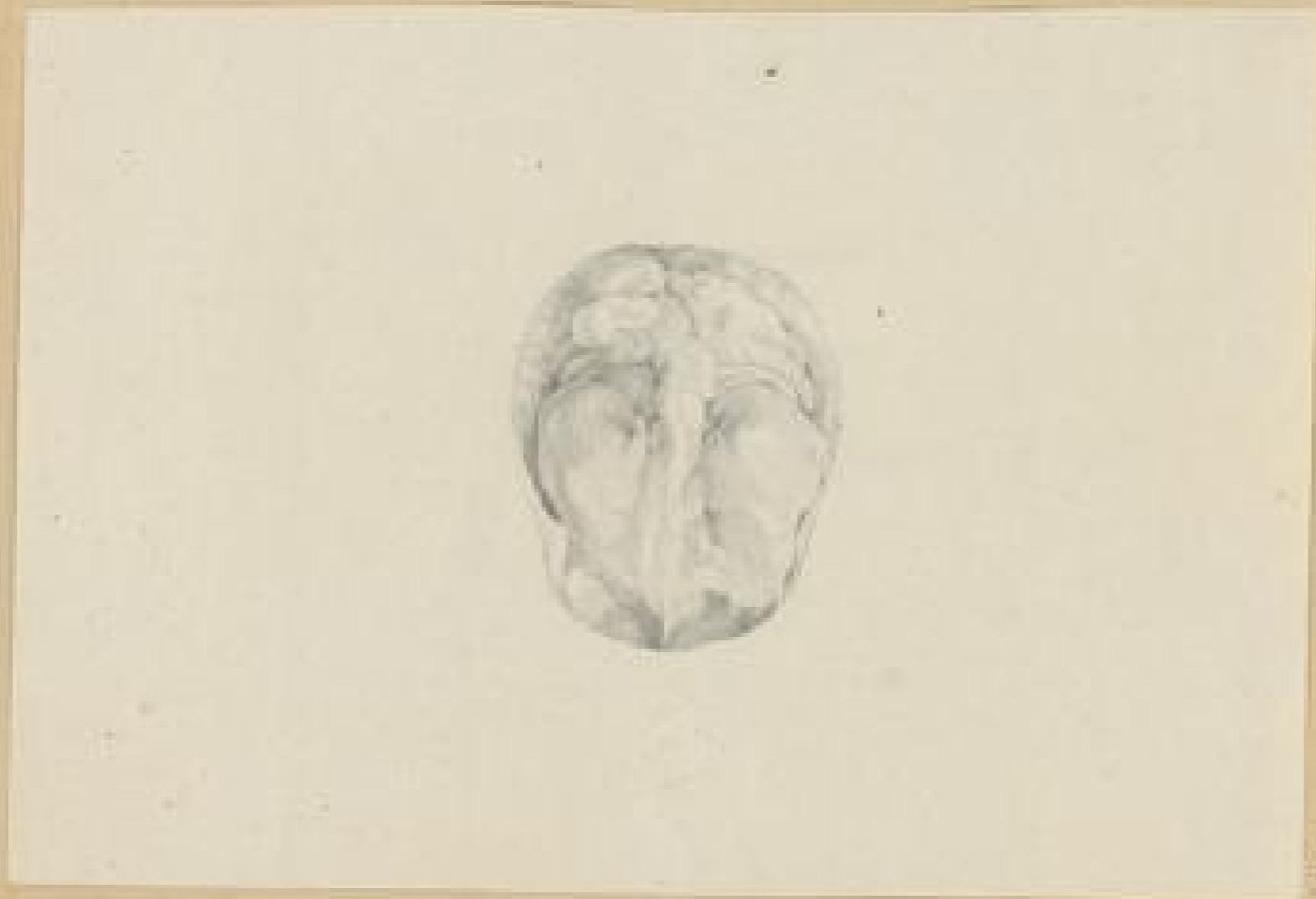II



106



107



108



Fig. 10.

Helix binae

Senckenberg

109

te

te

te

te

*Genova del. Kl. v. Rubens
pro*



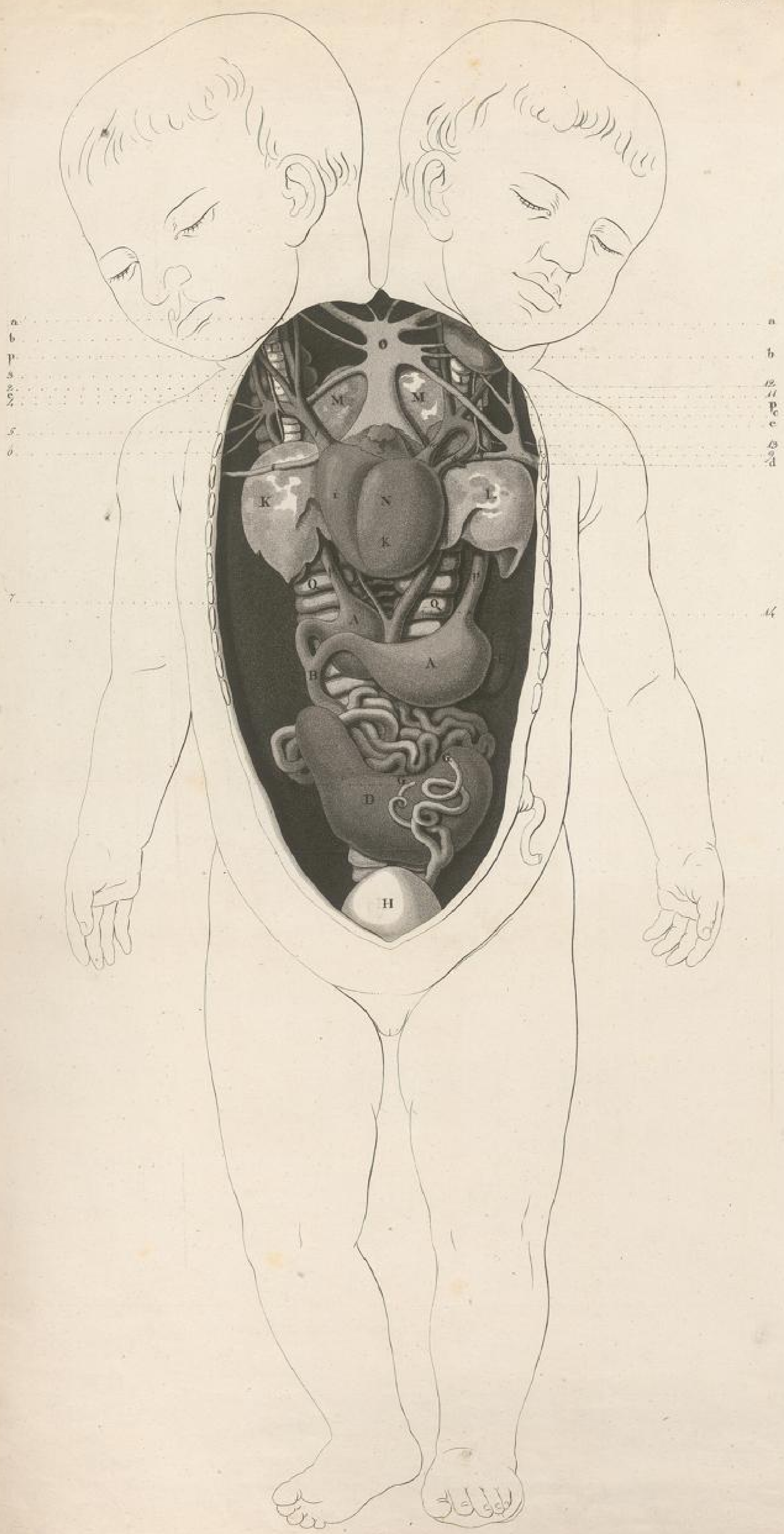
de

re

de

re

Tab. VI.



a
b
p
s
z
s
o

a
b
p
e
d

u

Sonm. Ch. Klein. Stuttgartae 1818.



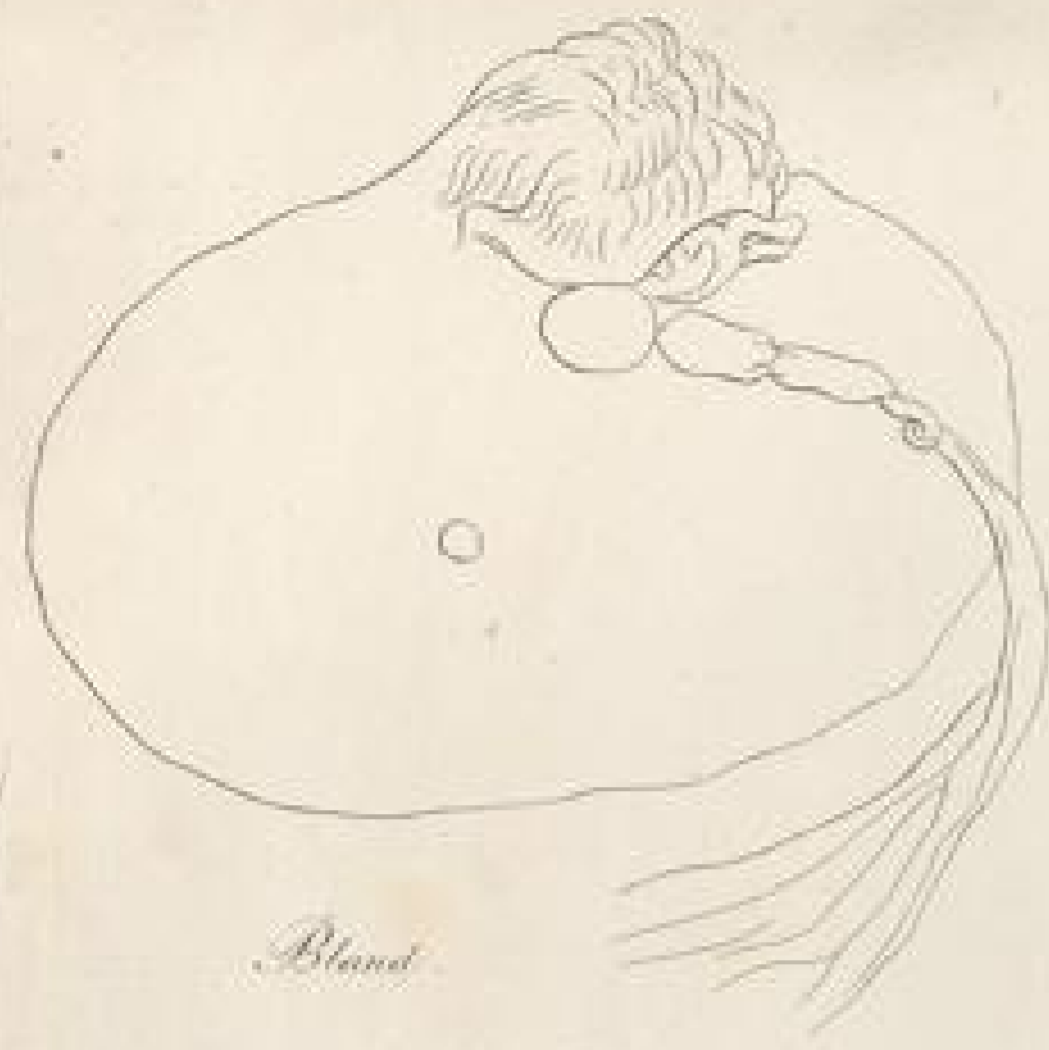de

re

on

ti





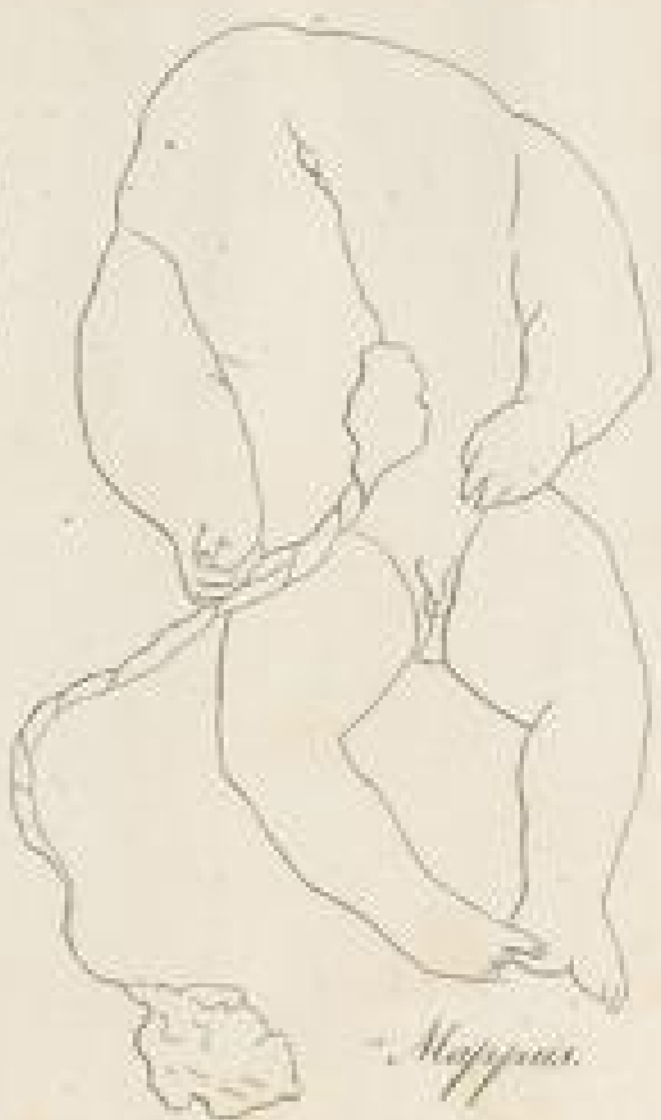Bland



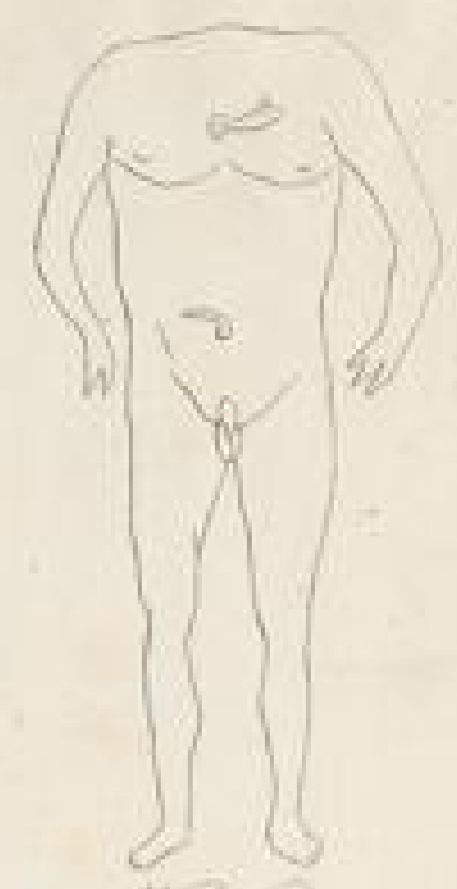Goeller



Daniel



Meyers



Kutschy



Reupf



Schellhammer



Klein



Volgel



Yonclaw, 1800

et Jonatione et Klein Nuttyntas 107

81

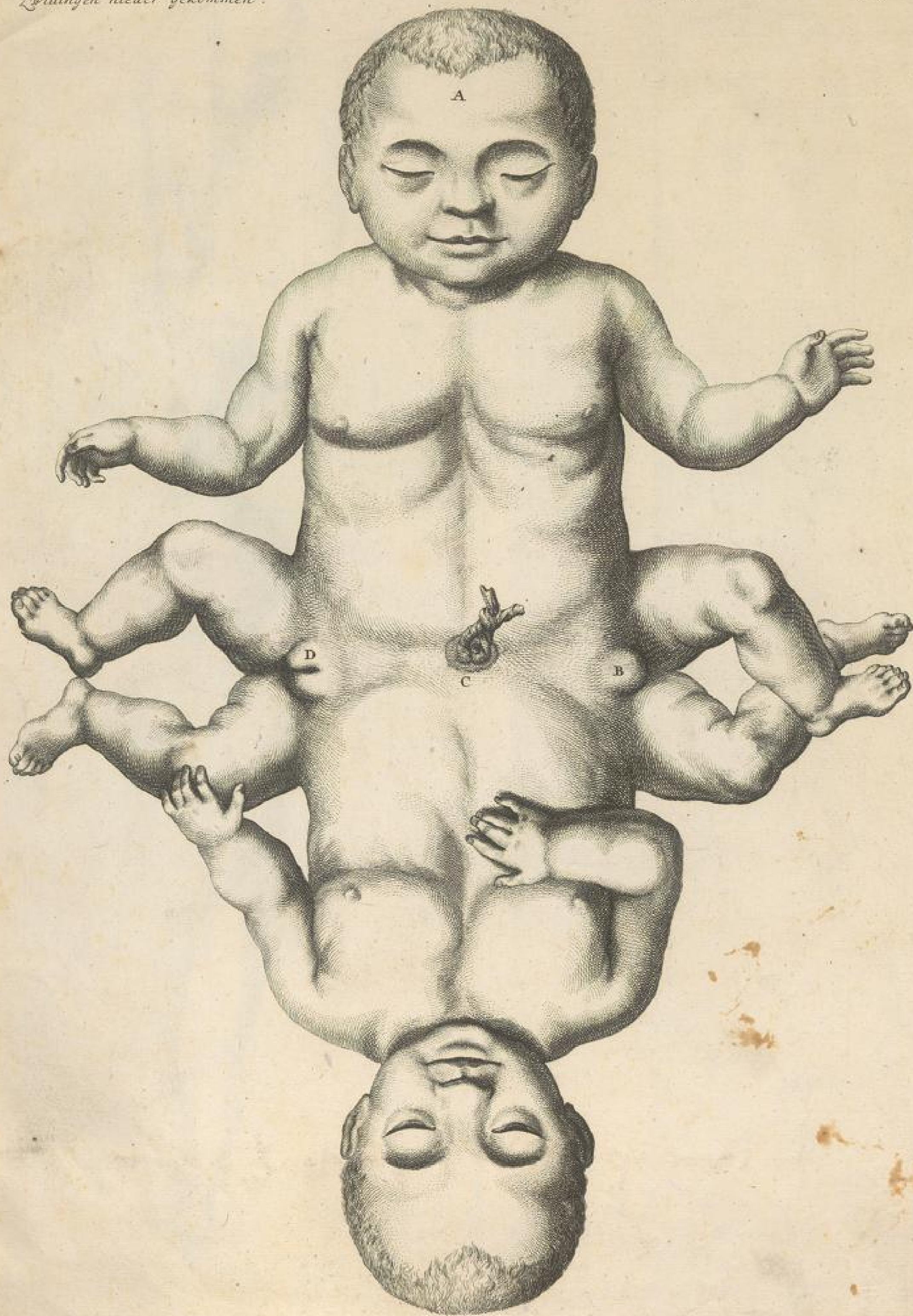13

14

15

Ein doppeltes Wunder Kind.

bestehet aus zwey an den hintertheilen des Leibs zusamen gewachsenen Kindern, welche beide den 31. May 1742. zwischen 3. u. 4. Uhr zu Zürndorff einem Marckgräf. Onoltzbachischen Ort ohnweit Nürnberg nicht nur lebendig an die Welt geboren, sondern auch noch selbigen Tag getauft, und mit dem Namen Heinrich und Barbara begabet worden. Sie waren übrigens von einer guten Gestalt, aßen etwas Zucker brod. u. ließen sich beide den Zuller gefallen. Sie hatten ihre Nabelschnur nebeneinander im Mittel des Körpers durch eine zieml. Öffnung des Leibs, wie in C zu sehen. Doch das Söhnlein A war am Ort B ohne Öffnung, wie es denn auch nicht recht mann. gestaltet gewesen, sahe von der Geburth her sehr blau, u. verschied daher bald. Ob nun gleich das Mägdlein wegen ihrer ordentl. Leibs beschaffenheit D gesund aussahe, mußte es doch wegen des zusamen wach. sens in die Ewigkeit nach wandern, welches zwischen 8 u. 9 Uhr den 1. Junii Vormittag geschehen. Der Vatter ist Georg Häßler, ein Schumacher, und ist von der Mutter merckwürdig, daß sie vor diesem schon 2 mal mit wohlgestaltten Zwillingen nieder gekommen.



121

Faint, illegible text, likely bleed-through from the reverse side of the page.



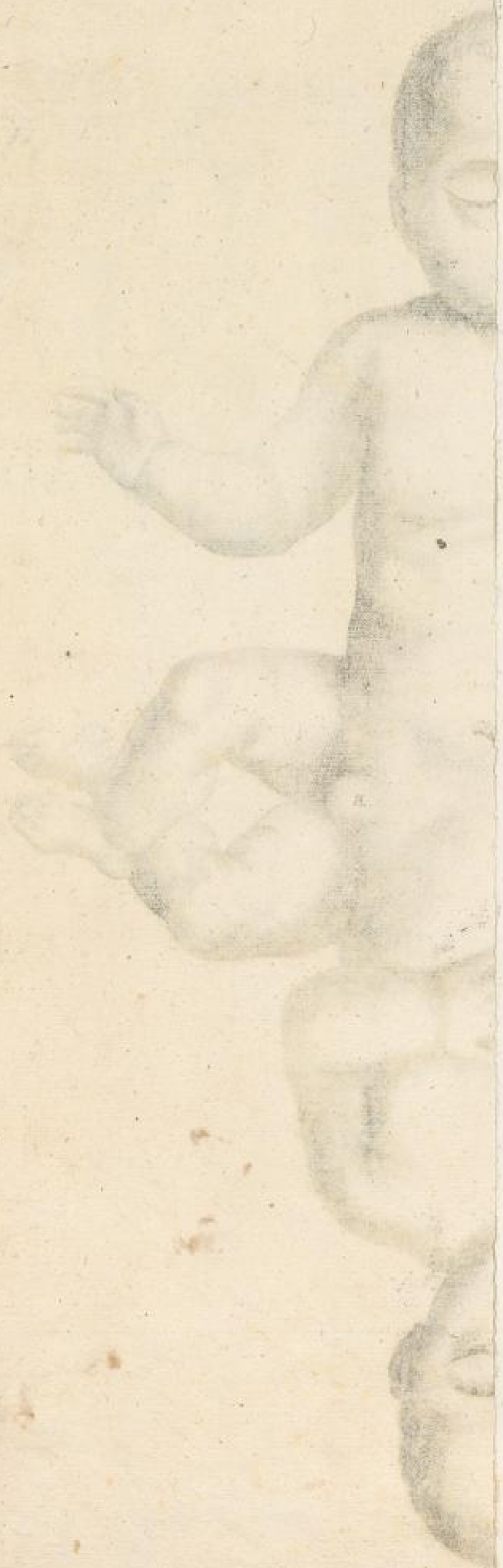
Tab. III.



Archetype fundatum pueri anni 10 collectum
 Regia. postgradual
 Don. C. Klein. 1813.

127

[Faint, illegible handwritten text]



DE

ER

ON

IT

128



Archetype servatur in Collectione Regia Stuttgartiae in finitima Vini
 Bonum et Antiqui Klein

Archetype in Klein u. Harter's Anatomicum 1815
 in Leipzig Chirurgie Dritter Band
 Leipzig 1813.

107

Handwritten text, likely a list or index, with several lines of cursive script. The text is mostly illegible due to fading and the condition of the paper.



6

RE

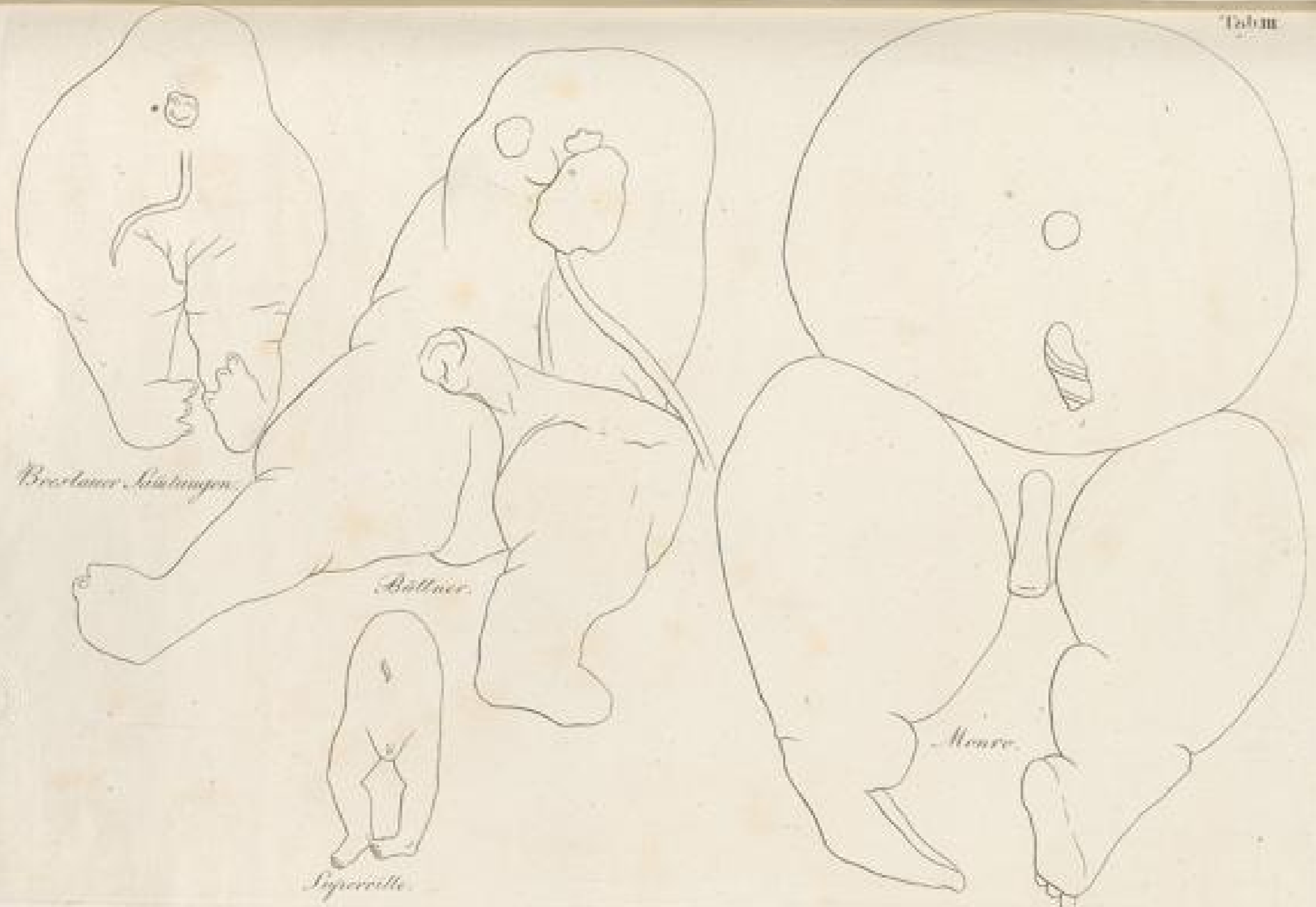
DI

II

II

II

II



Fœtus in statu proleto, Hüllhäute
1717

127

[Faint, illegible handwritten text]

6

127

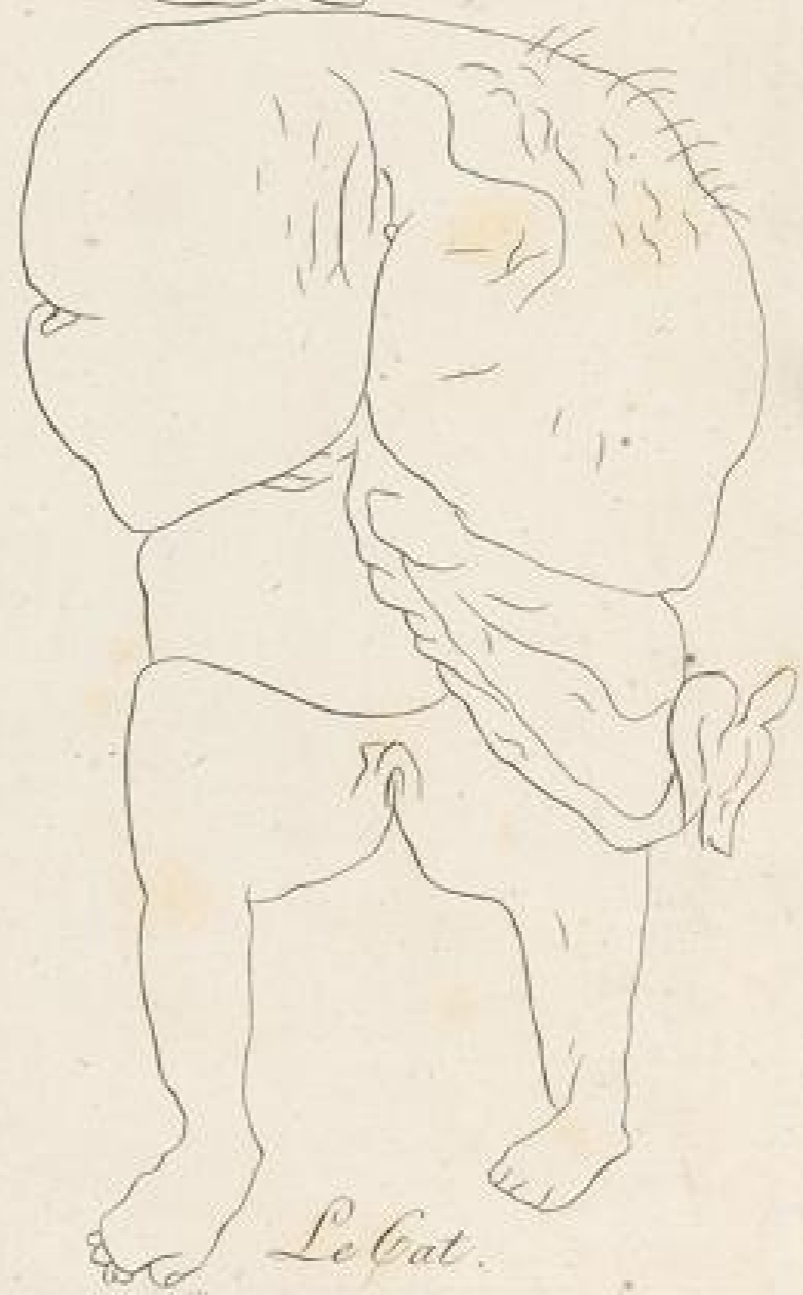
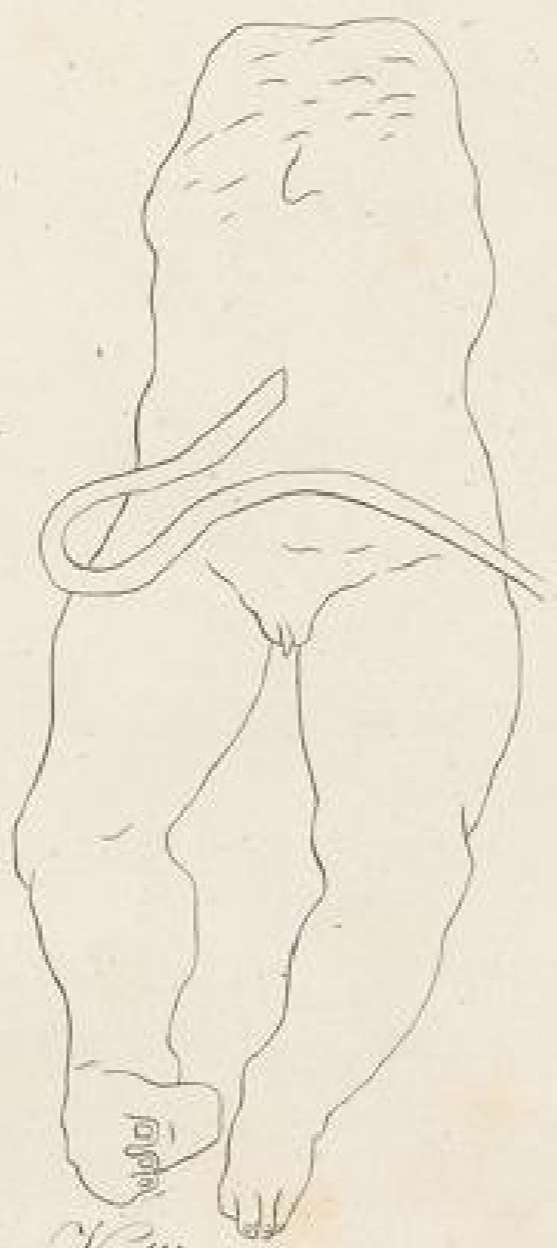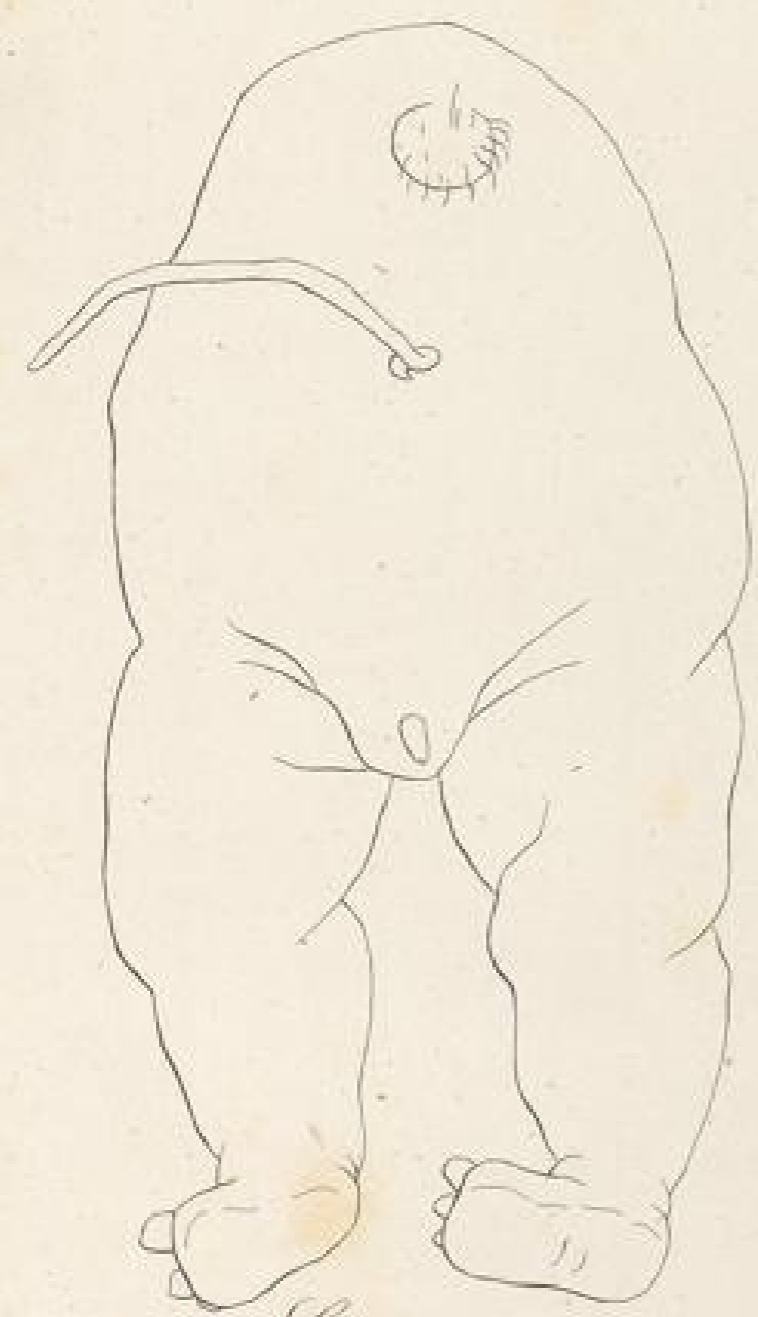
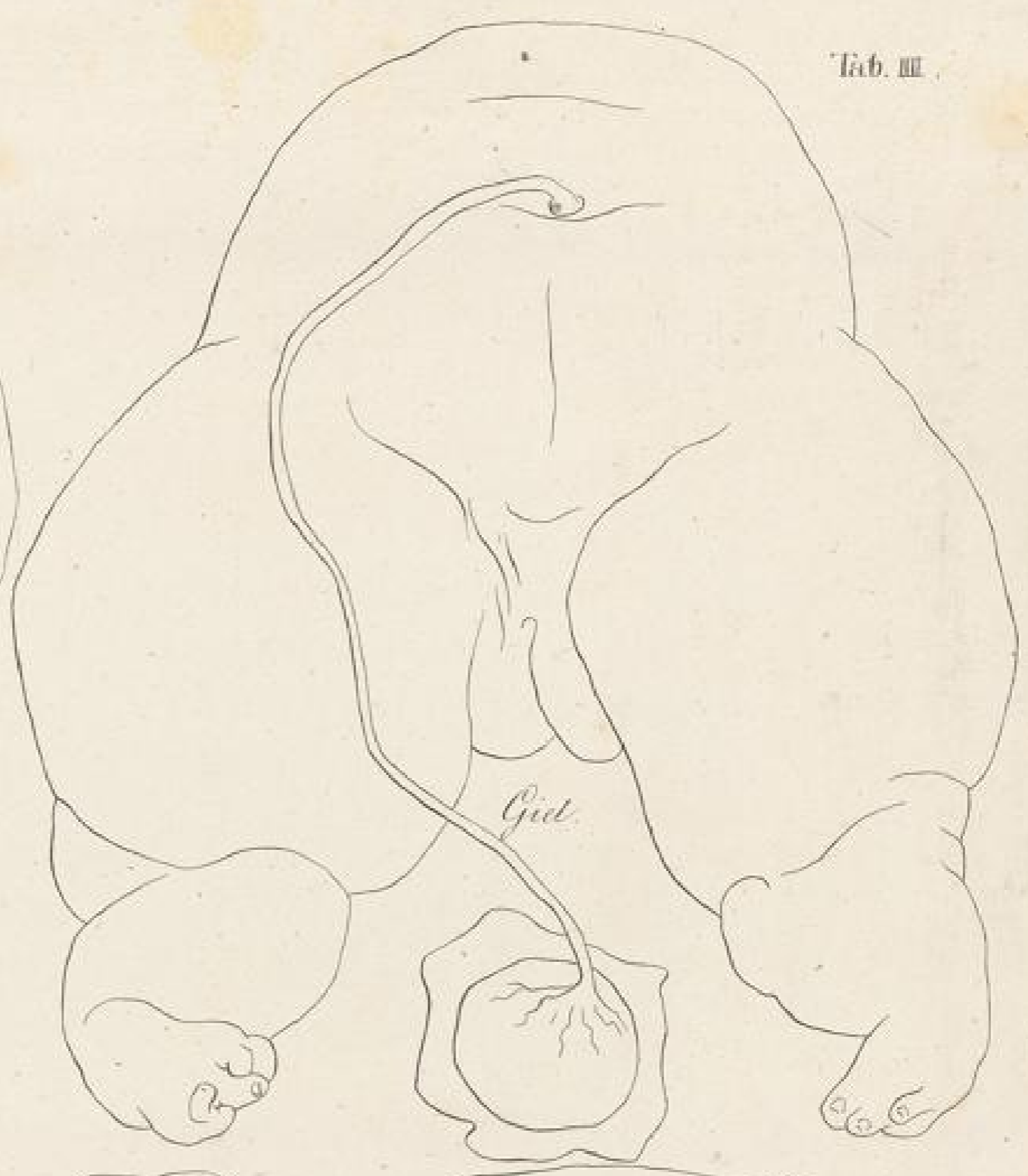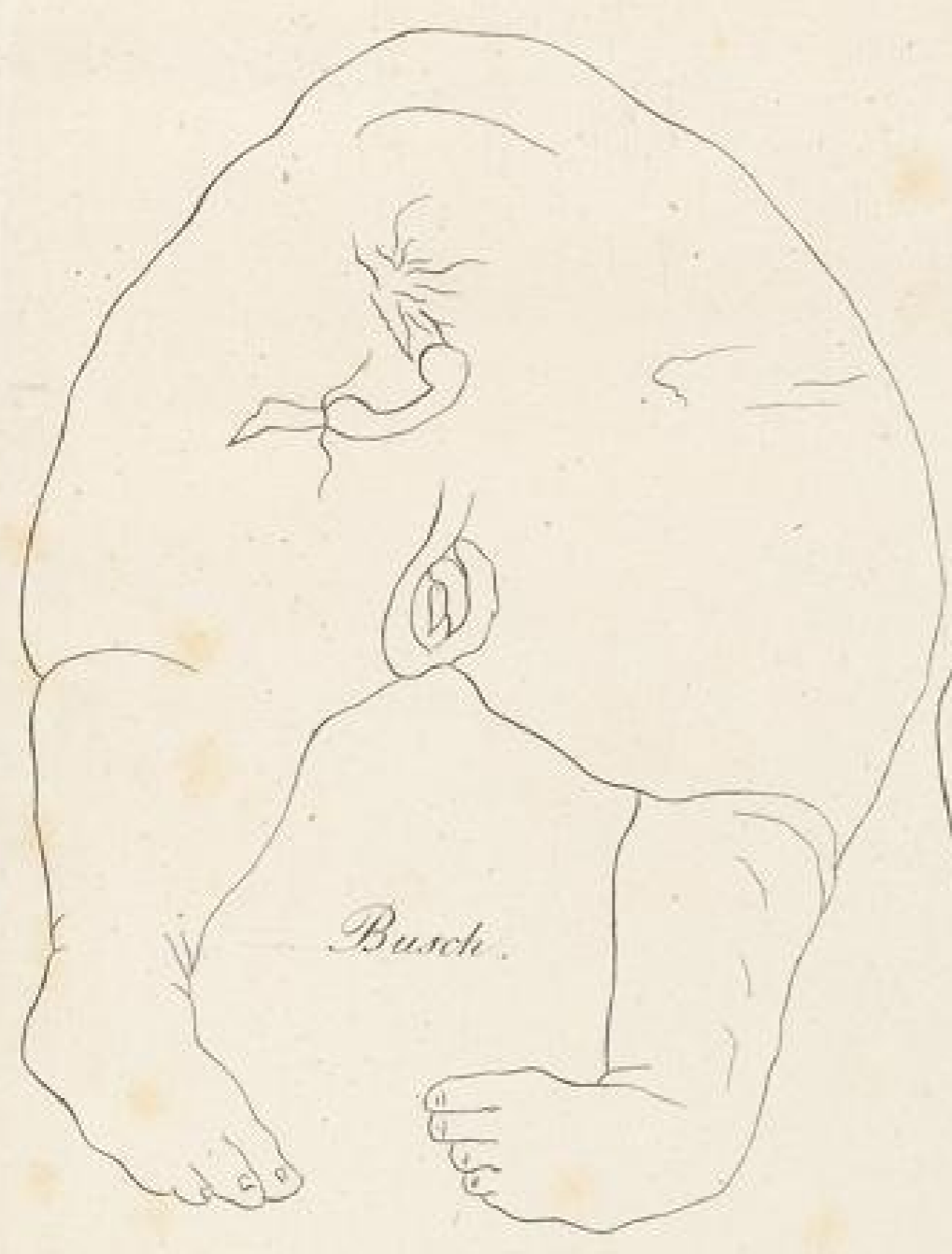DI

127



127

Tab. III



et. Klein Stuttgartiae 1813.

Θ

FE

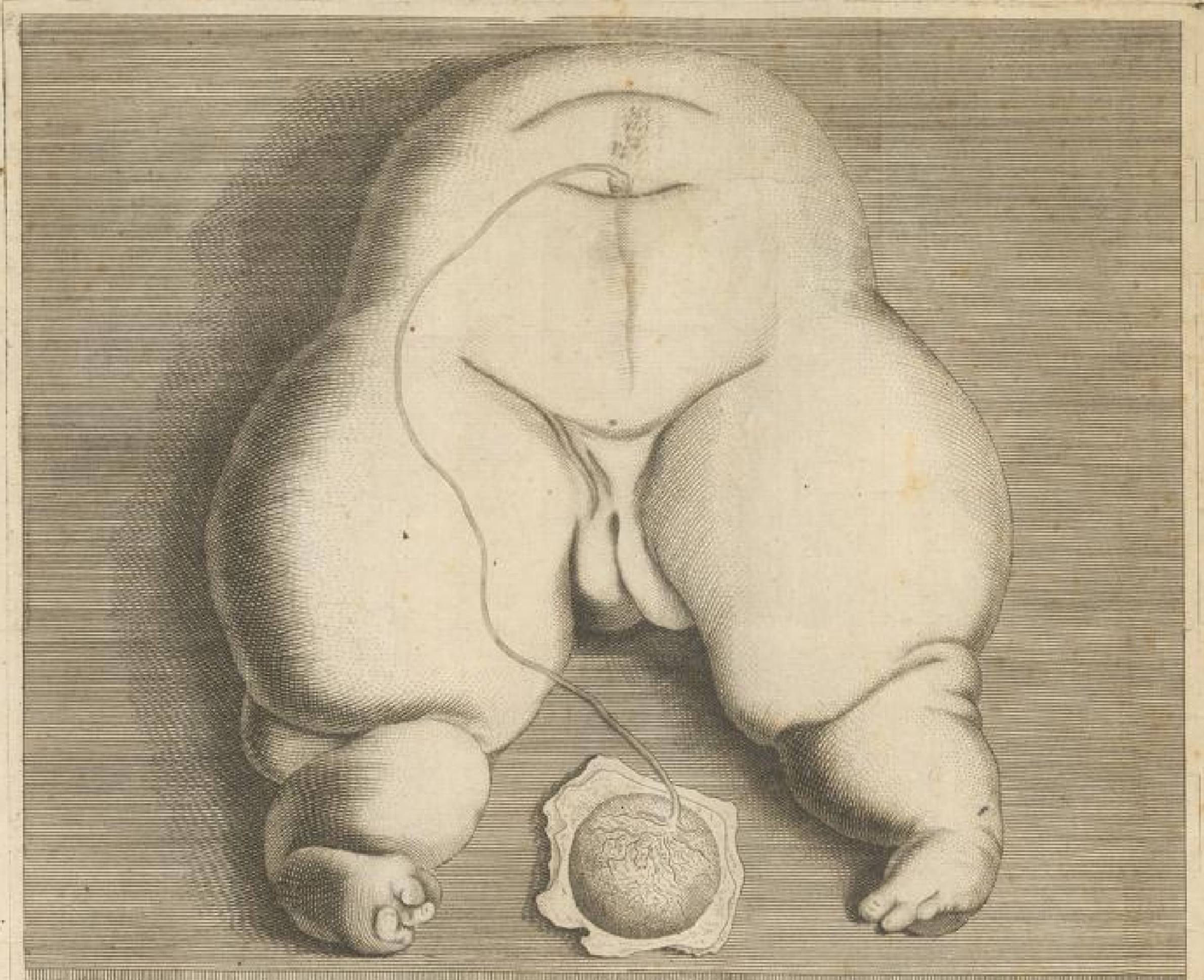
DI

TI



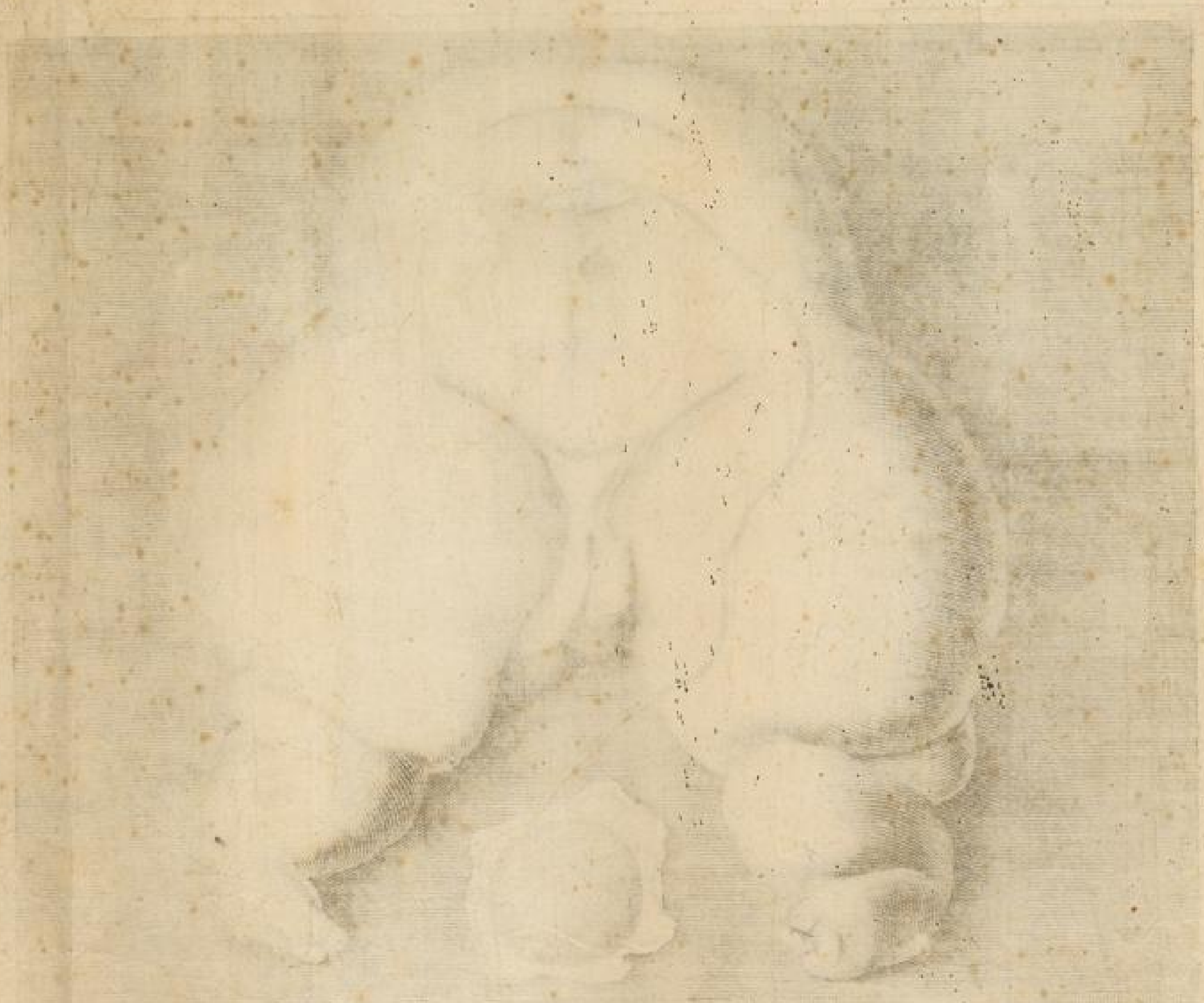127

128



Monstruosus hic partus in Lucem prodit 4^{to} Julij 1773 Monachij in Bavaria edita una hora prius a Matre puella q^{ue} Monstrum
 incolunt figura erat quam Icon exhibet Jopplicus gallos longa lata & secta Anatomica detexit omnia ossa Pelvis et pedum excep-
 tis in utroque geminis diatis Cavitas pelvis dextra major et amplior sinistra continebat in se omnia Intestina tenuia et Crassa
 e Rembus dexter aderat sicut et Uterum vesica ac Genitalia sexus foeminei cum congruis Arterius Venis et Nervis de
 Corde pulmonibus Hepate et splene &c sicut et de Capite Thorace brachijs nullum inventum testigium fecit
 Jacobus Giel Sen. Provic.
 et Metropol. Chir. et Obstetric.

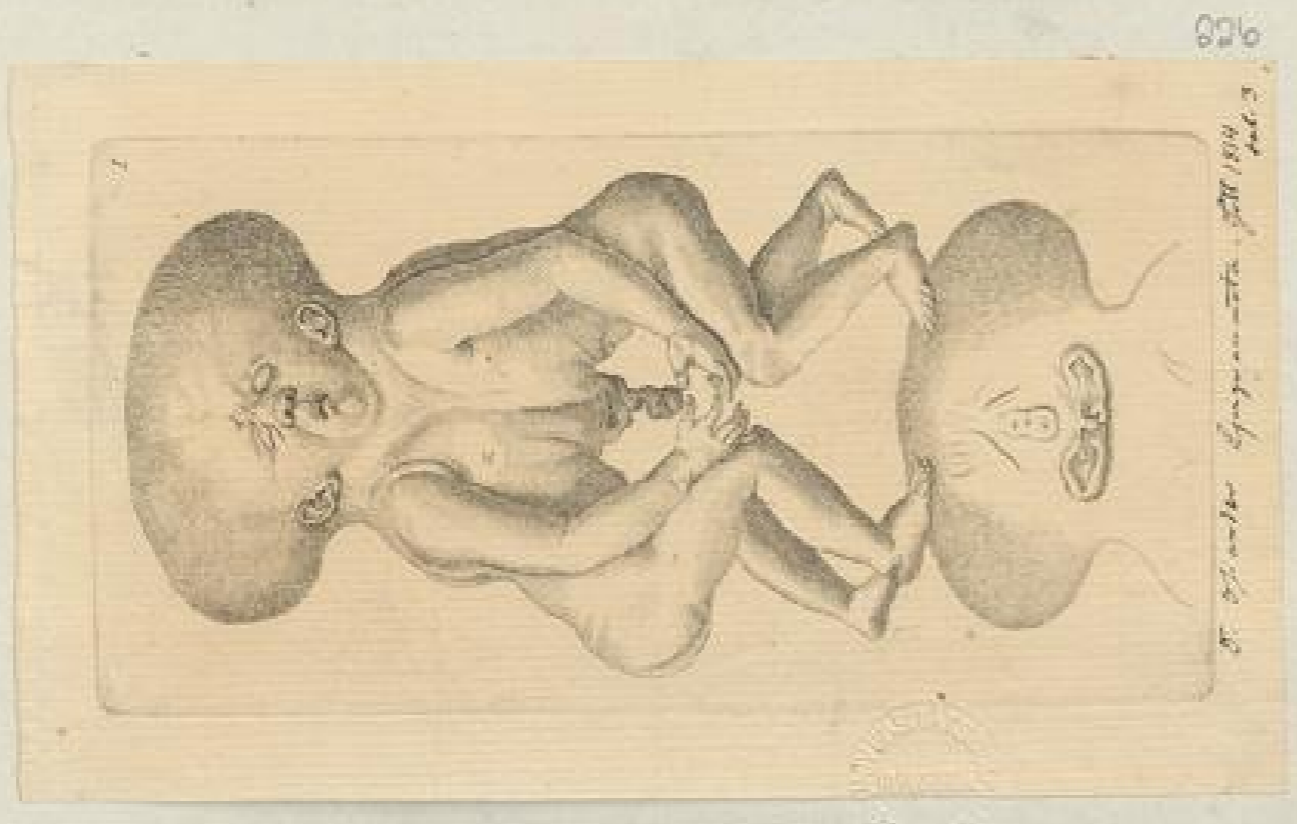
Pinxit G. Schaeffer Sculpit J. G. Schaeffer 1773




Faint, illegible text or a caption, possibly describing the anatomical drawing above. The text is too light to read clearly but appears to be organized into several lines.



174





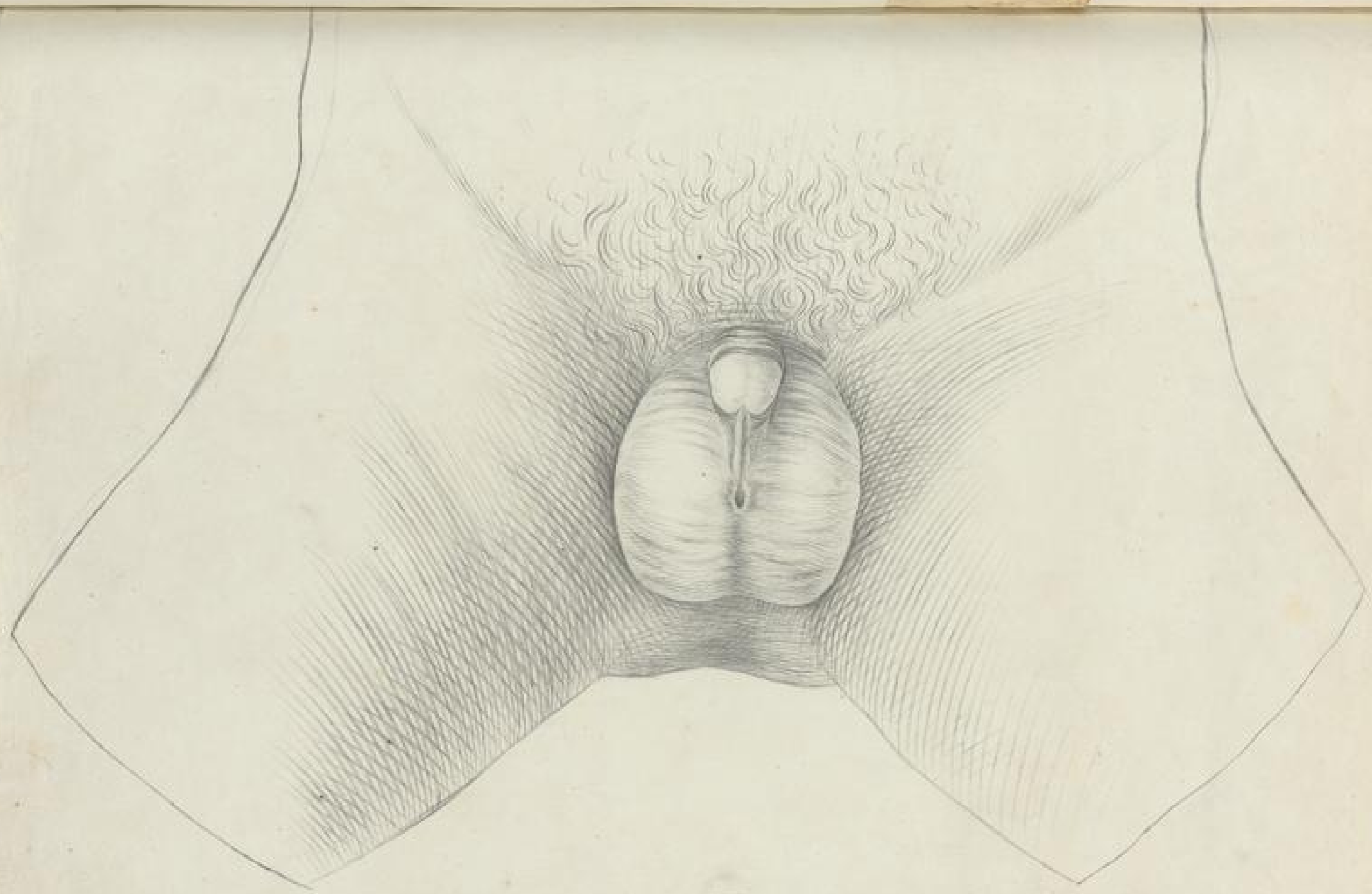
8

HE

DI

II





Maripatha Bergfeld - *Leinpfel*
August 1820 von Prof. Nitzsch

1820
Nitzsch

Θ

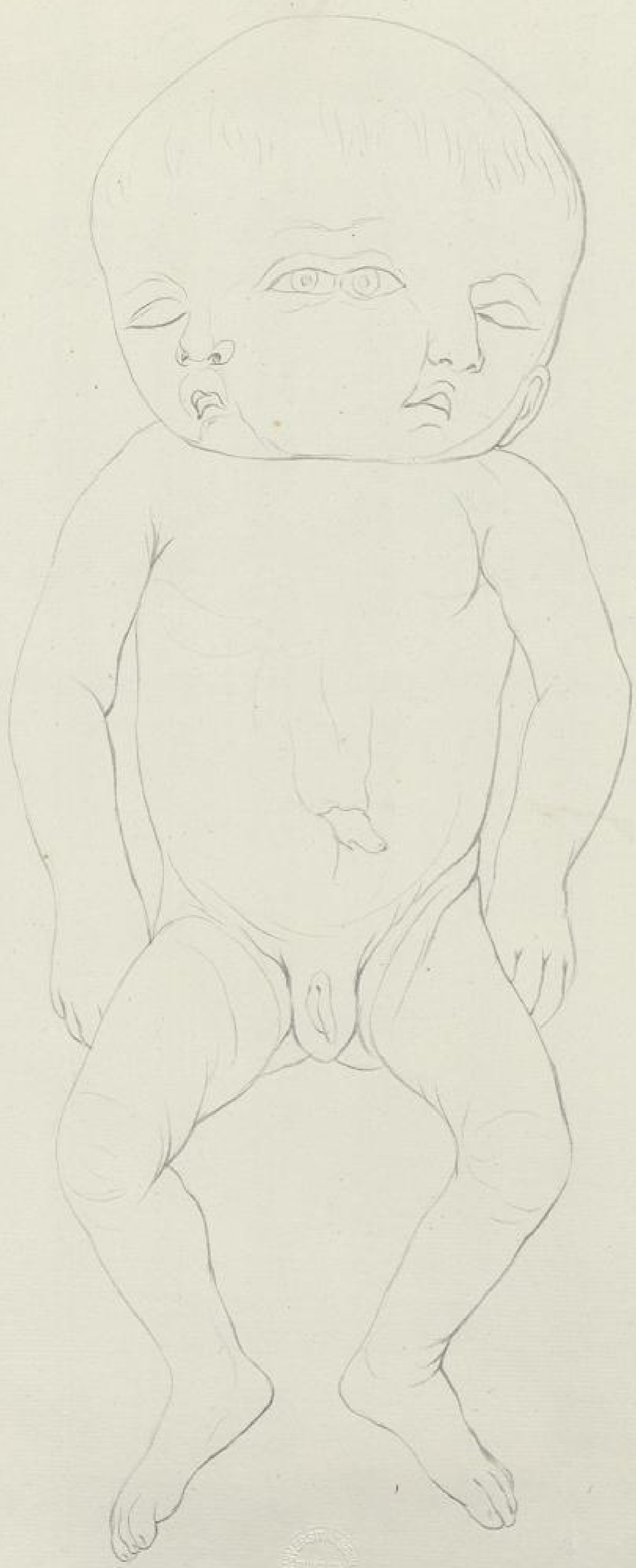
ΠΕ

ΟΙ

Τ



pag. 24



Præsent icon in theatro anatomico retinetur in natura sub numero 1. Anno 1773.

Solger del.

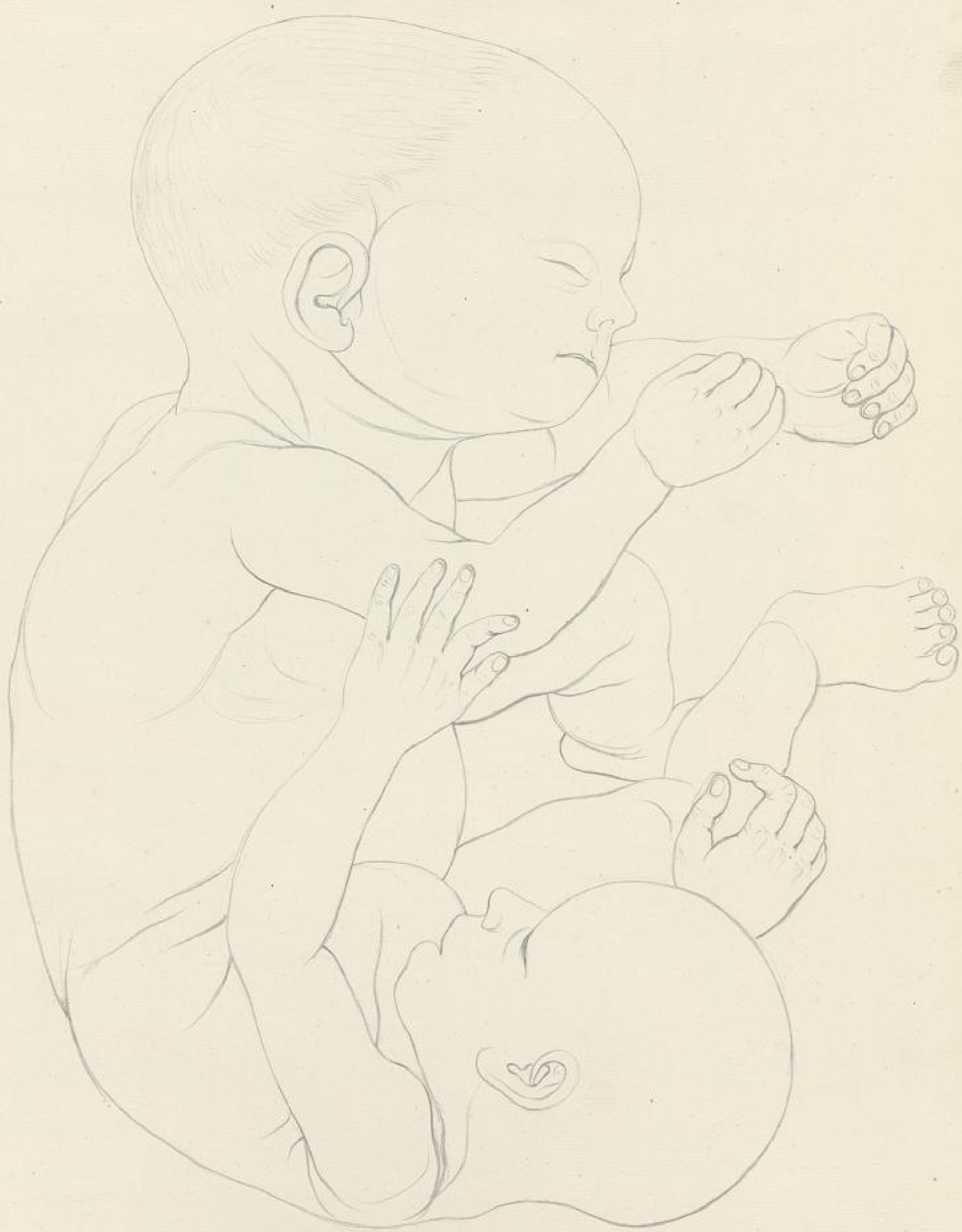8

TE

DI

IT





Idem monstrum ab alio latere.




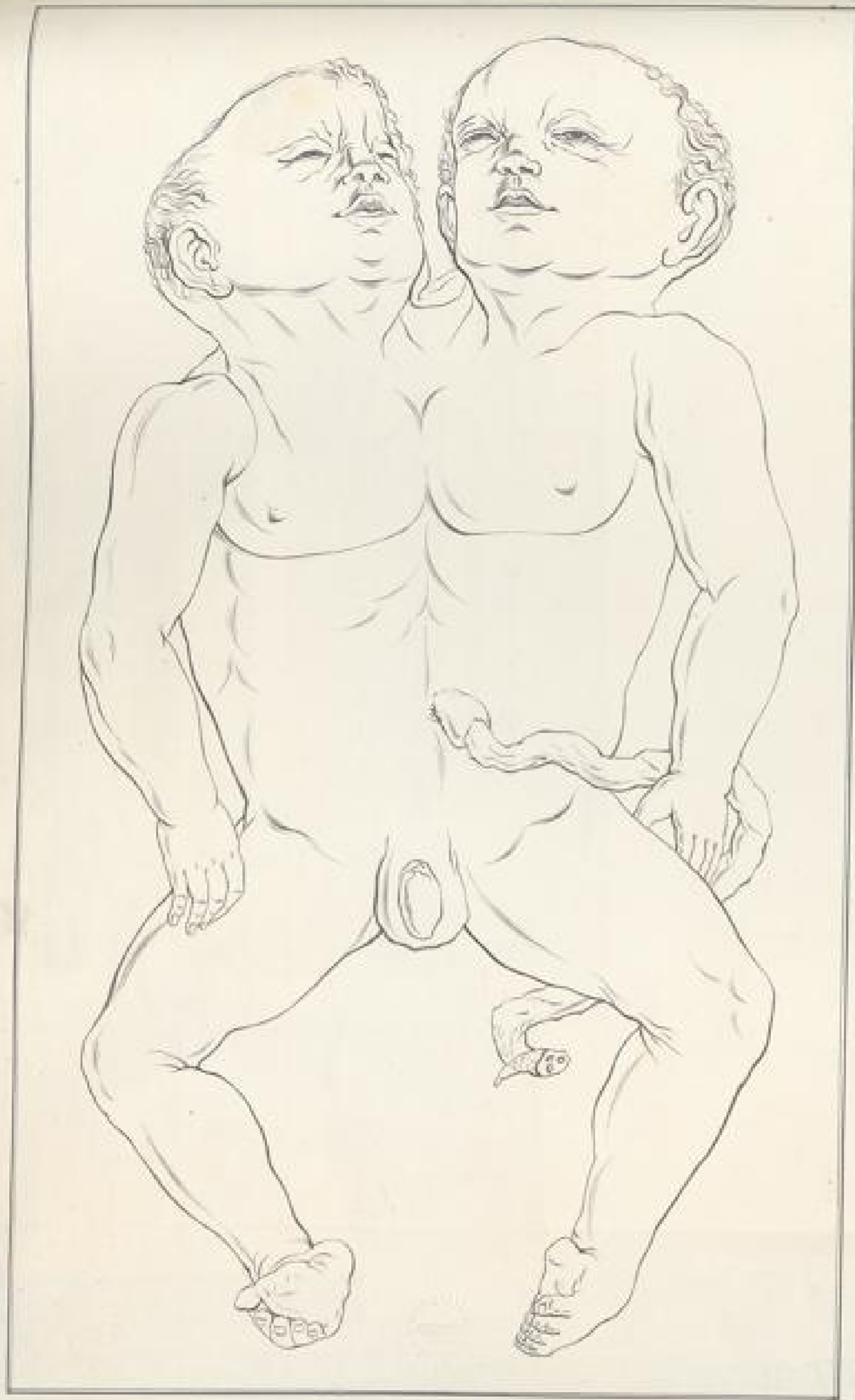
8

12


01

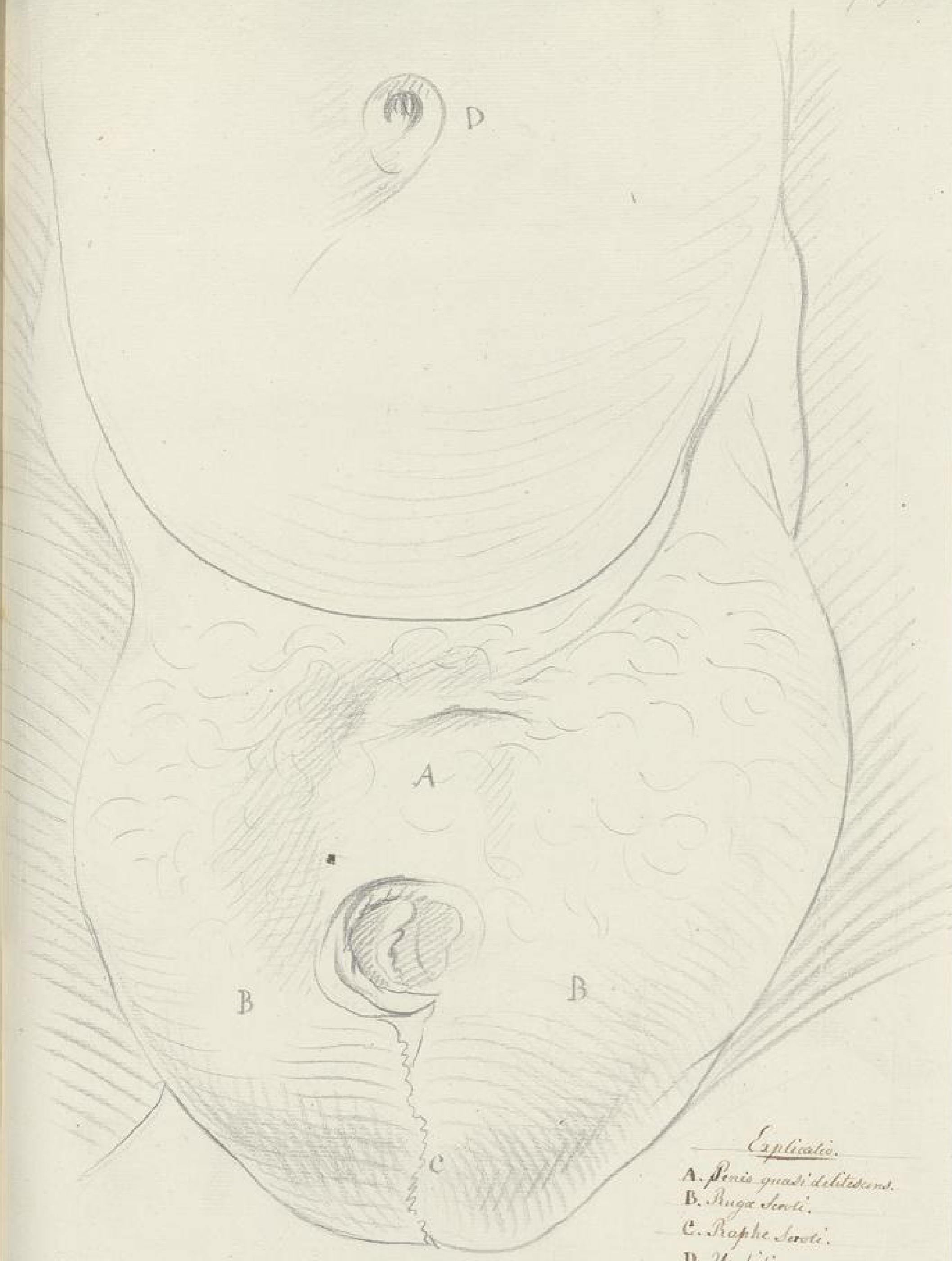
11





*Die hier abgebildete Verbindung zweier Kinder von der Brust abwärts getrennt
kann als ein Beispiel der abdominalen Verbindung betrachtet werden.*






Explicatio.

- A. Penis quasi relictus.
- B. Ruga scroti.
- C. Raphe scroti.
- D. Umbilicus.

*Haec icon representat Hydromelen a priori in utroque latere scroti
hauritum et secundum veram magnitudinem delineatum.*

Gezeichnet von Michael von Jägermeister P. Licholeppest den 28. Januarii 1786.





8

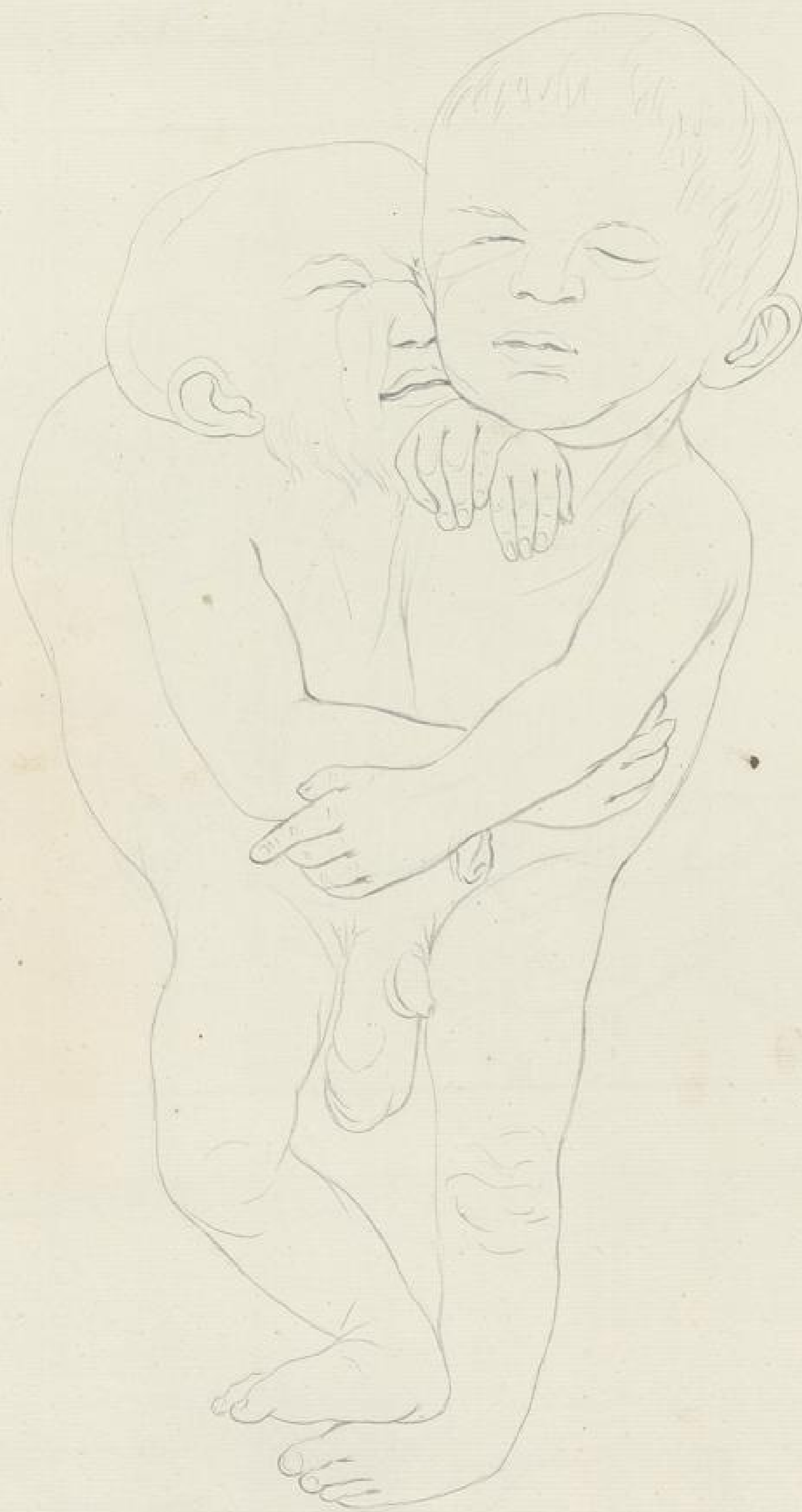13

01

11

116


Fig. 2²⁸



Hec monstrum in natura a seorsum in theatro anat. moscuensi

(Saltzer del.)





a

E

O

T




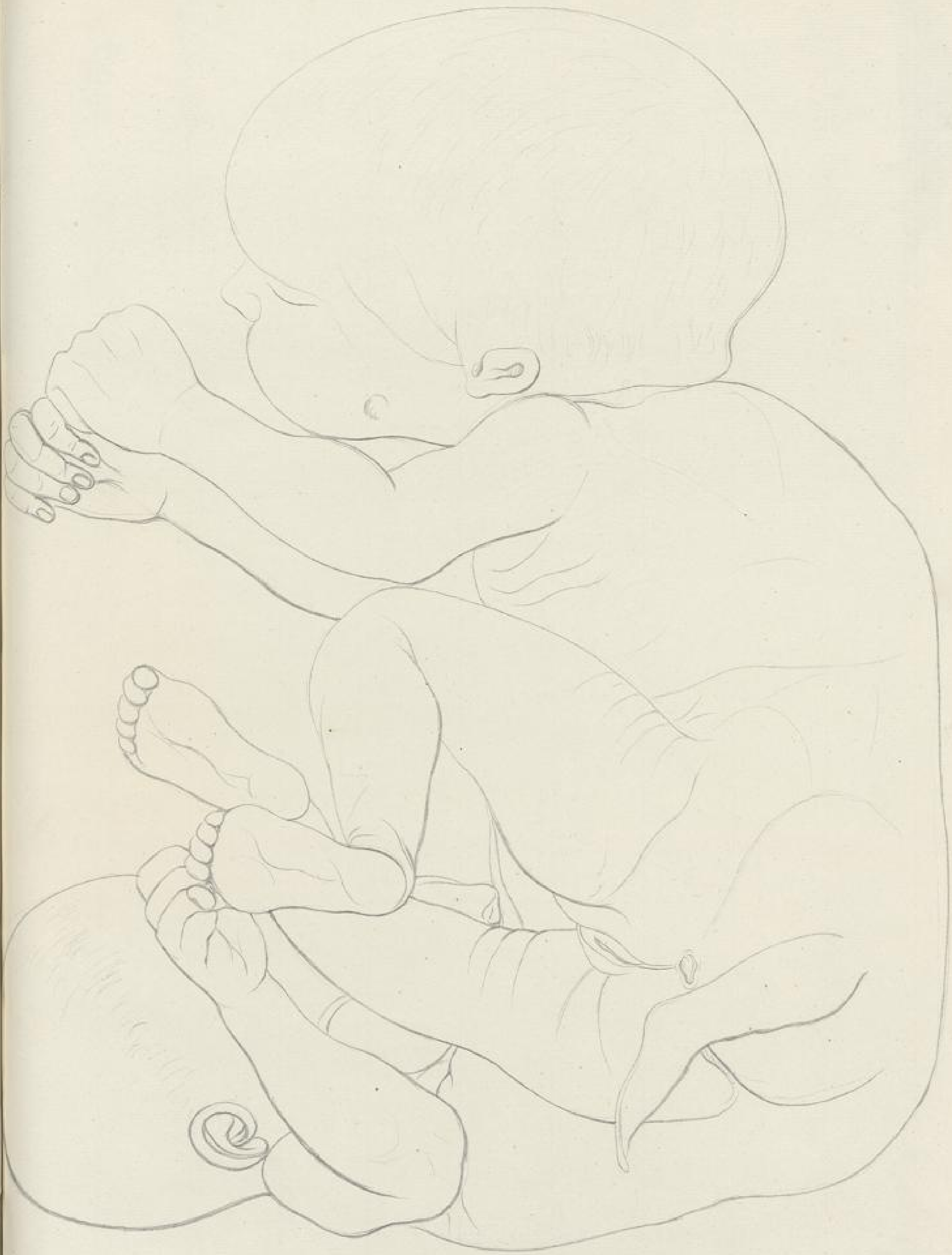
Die Muskeln in dieser nach hinten



Fig. 2. 30

31





*Hoc monstrum jussu collegii Imperialis nr. e collectione theatri anatomici moscuensis
Petropolini missum.*

Hoc monstrum in collectione nostra servatur.

8

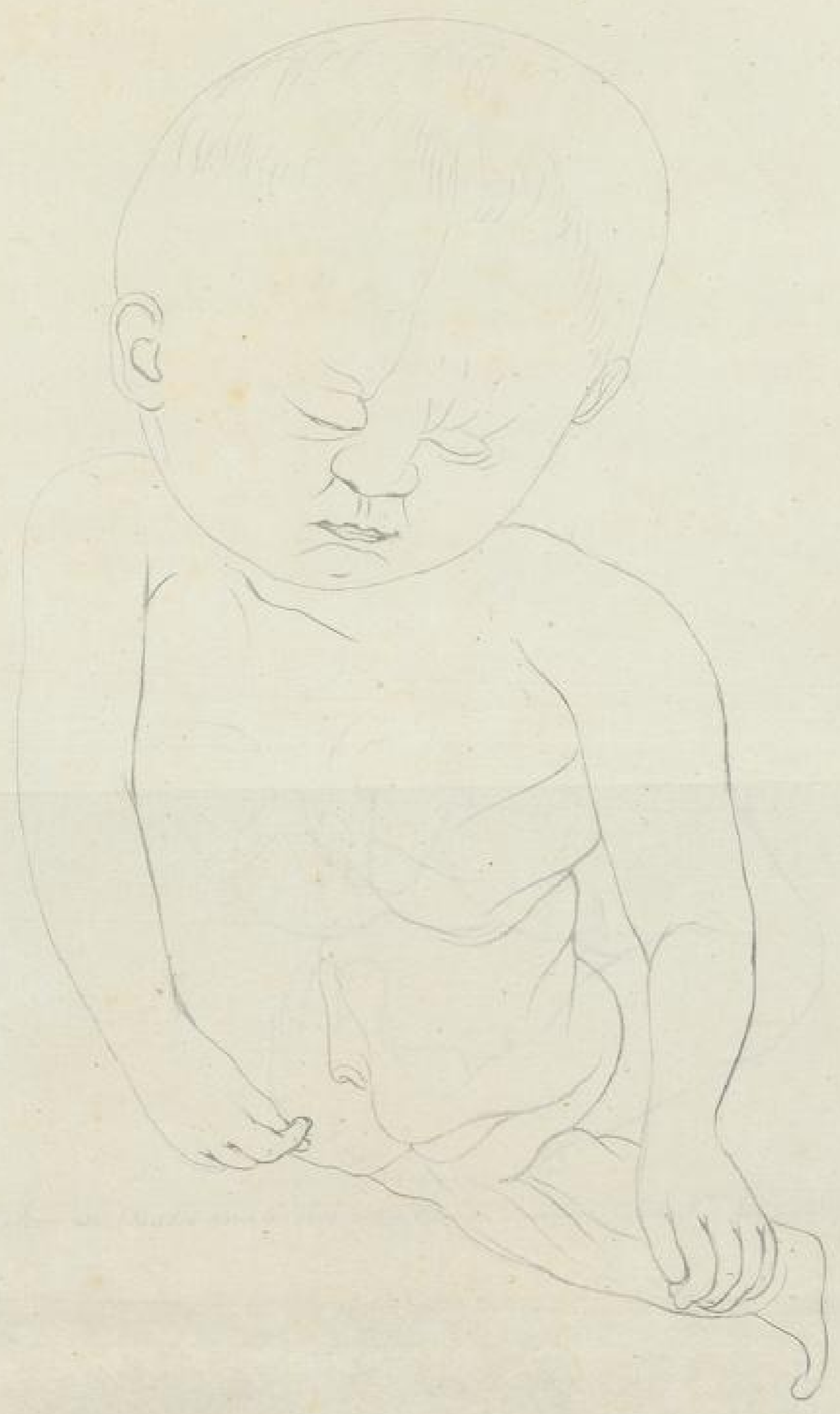FE

DI

II

113

May 12



Hoc monstrum in collectionem nostram pervenit.

6


HE

01

IT



Infans Iren in theatro anatomico retinuitur in natura sub N^o XII. anno 1774 (Sulzer del.)



3

12

01

11


11

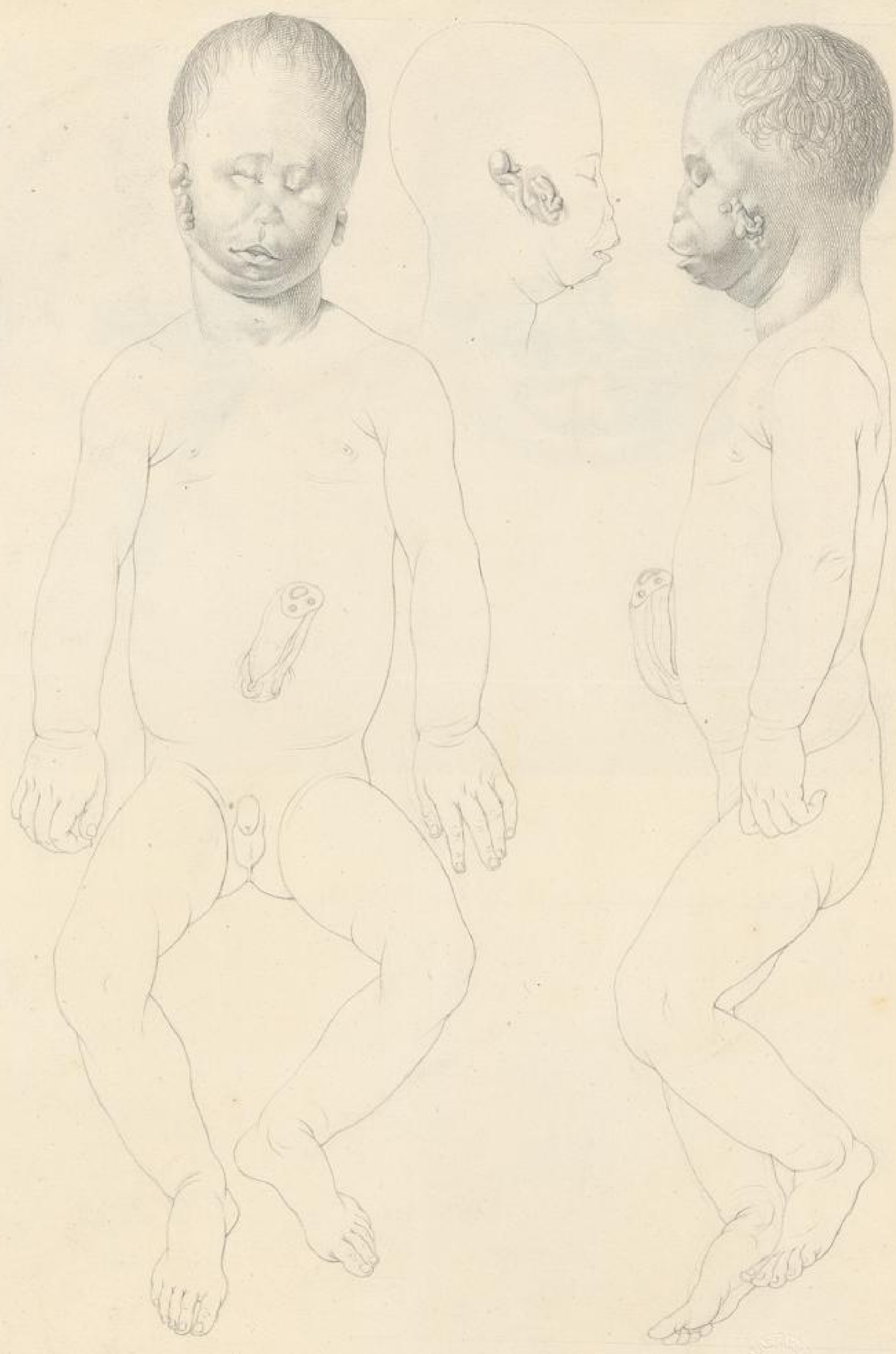11

aug 1711 33



*Hoc monstrum antea in nostra collectione monstrandi observatum fuit, nunc vero jussu
 collegii medici imperii Academiae Imperialis Scientiarum
 adjunctum.*





6

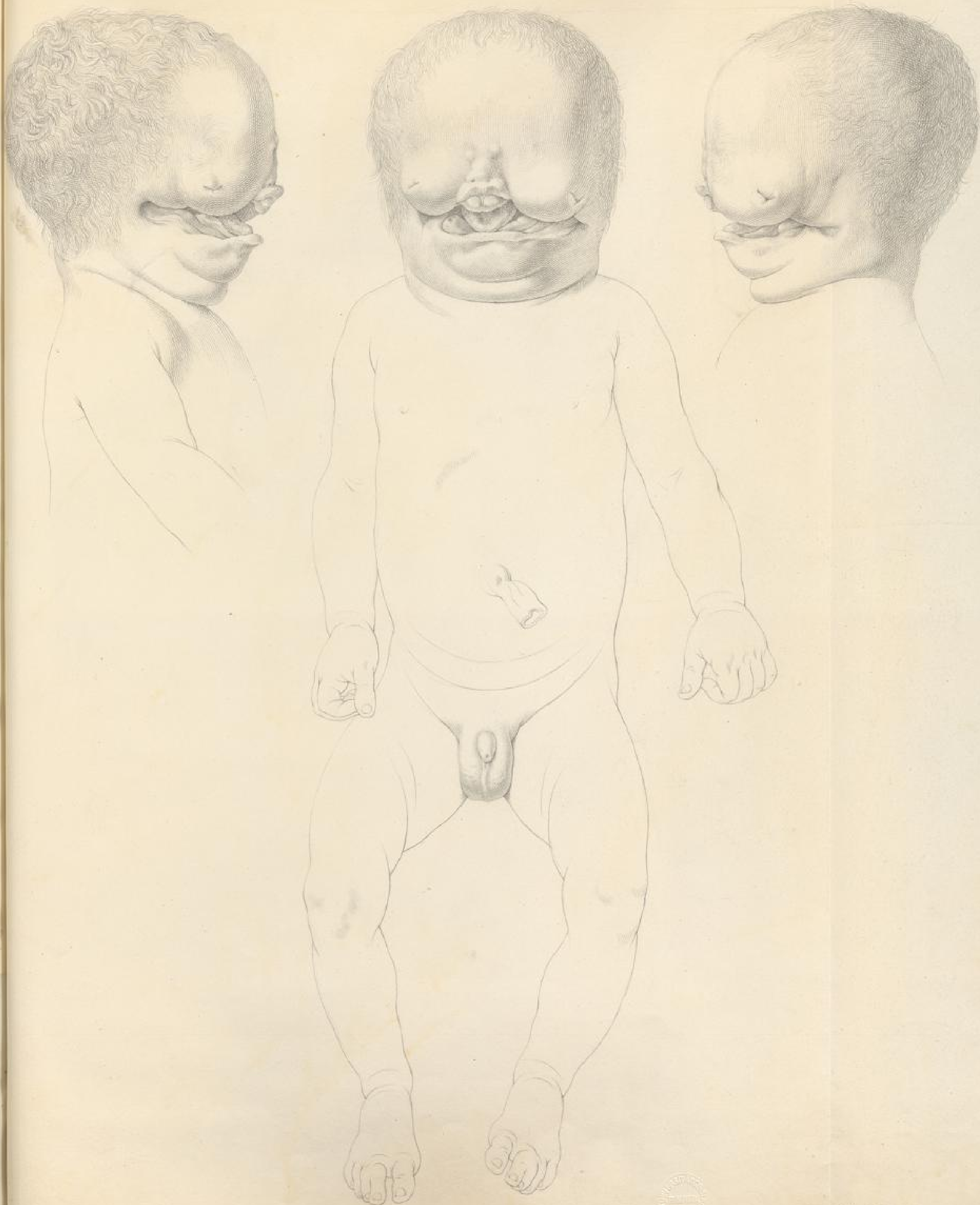
15

10

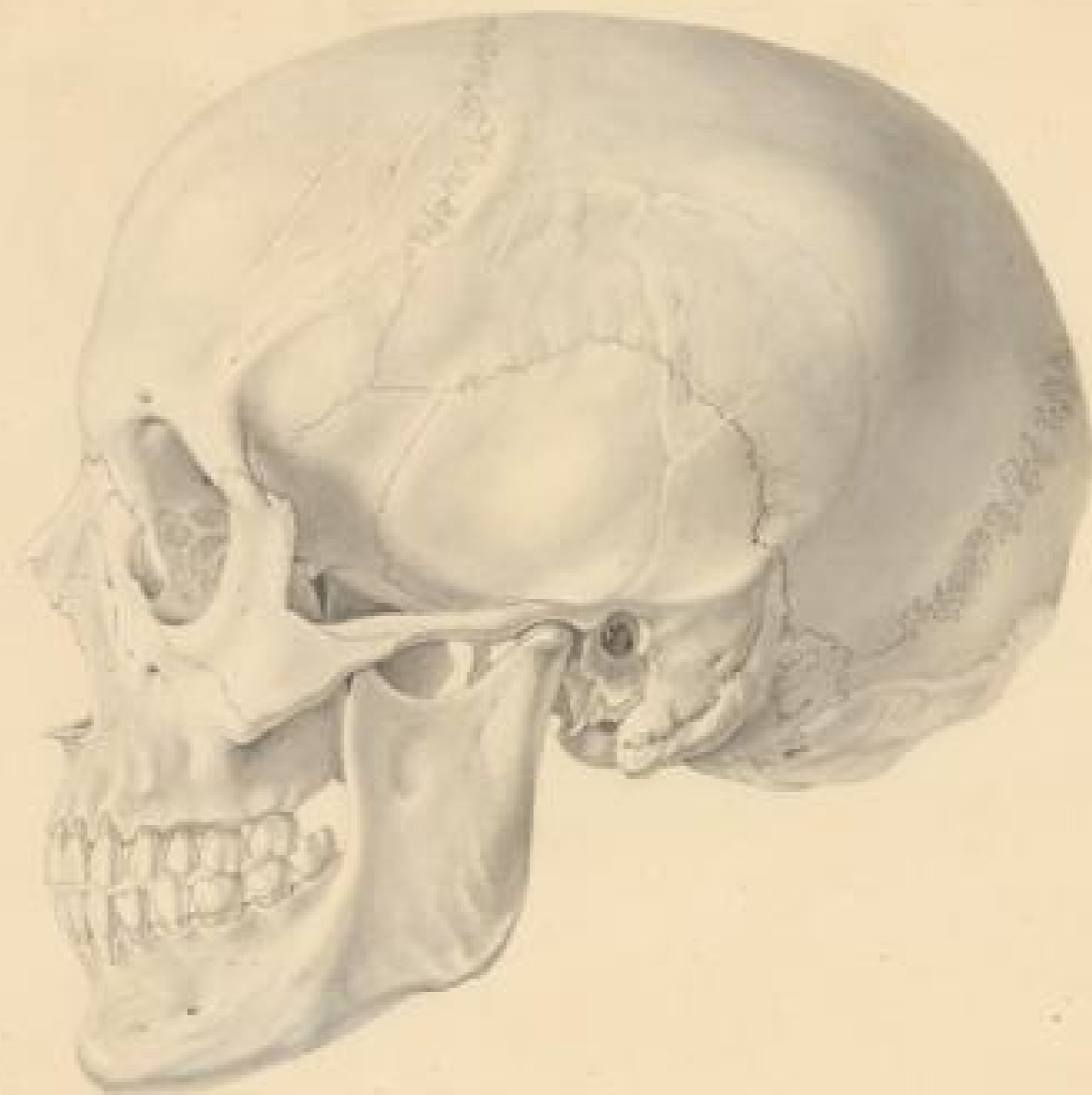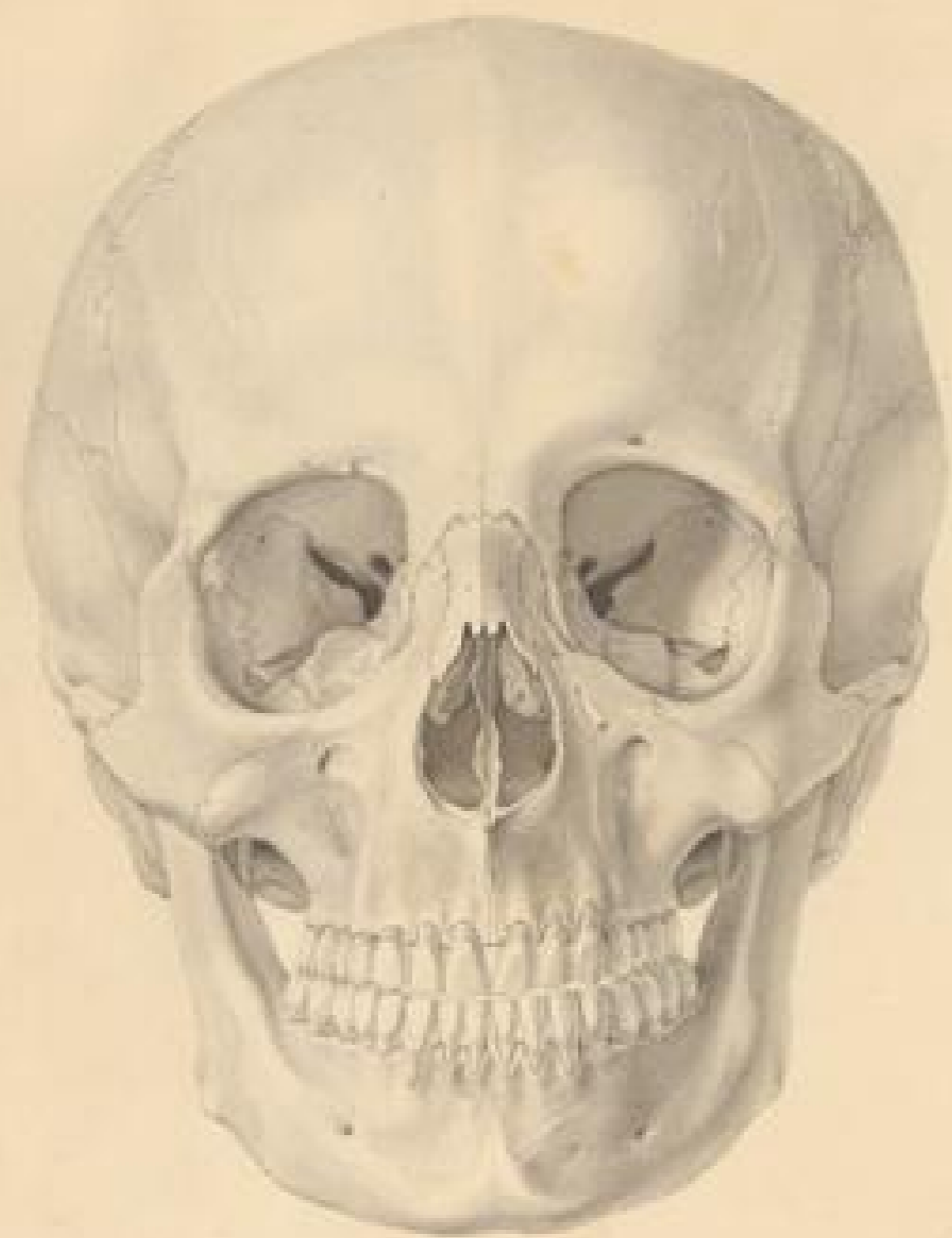11

10

110

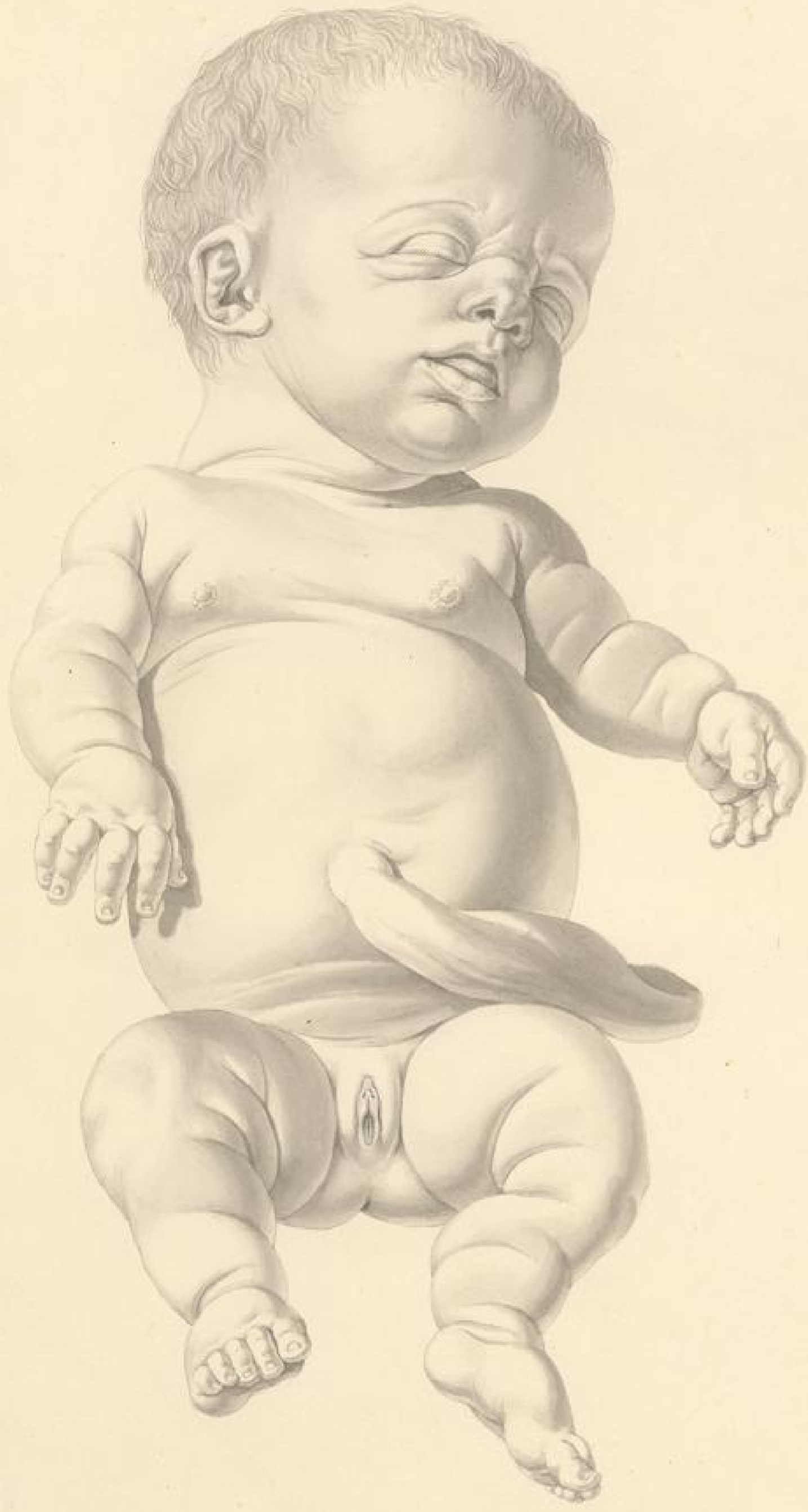

Christ. Baur. del. et sculp.



Georgianerin aus Hunsbachers Sammlung nochmals gezeichnet von Kraus 1814 Jul.





Child Robert B. subject.

38
 39
 40
 41
 42
 43
 44
 45
 46
 47
 48
 49
 50
 51
 52
 53
 54
 55
 56
 57
 58
 59
 60
 61
 62
 63
 64
 65
 66
 67
 68
 69
 70
 71
 72
 73
 74
 75
 76
 77
 78
 79
 80
 81
 82
 83
 84
 85
 86
 87
 88
 89
 90
 91
 92
 93
 94
 95
 96
 97
 98
 99
 100

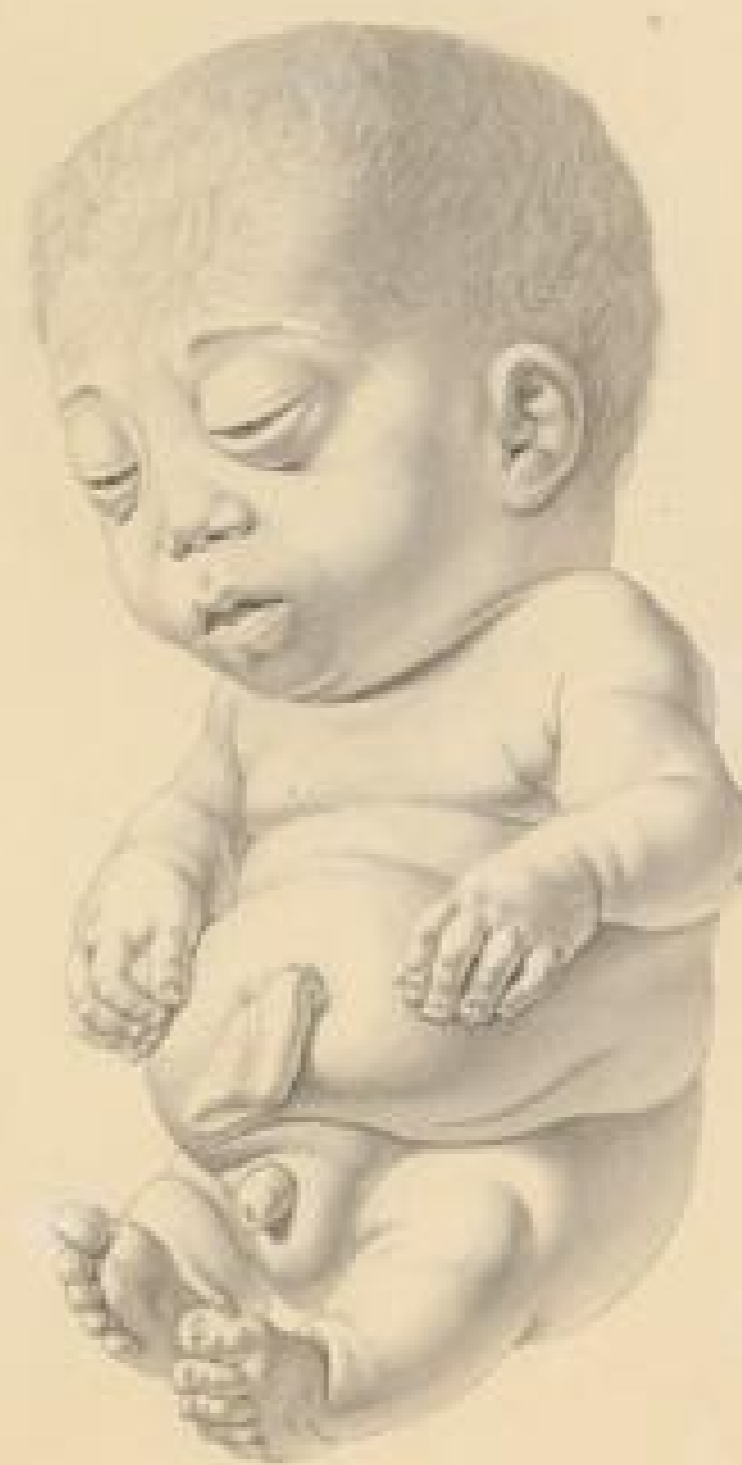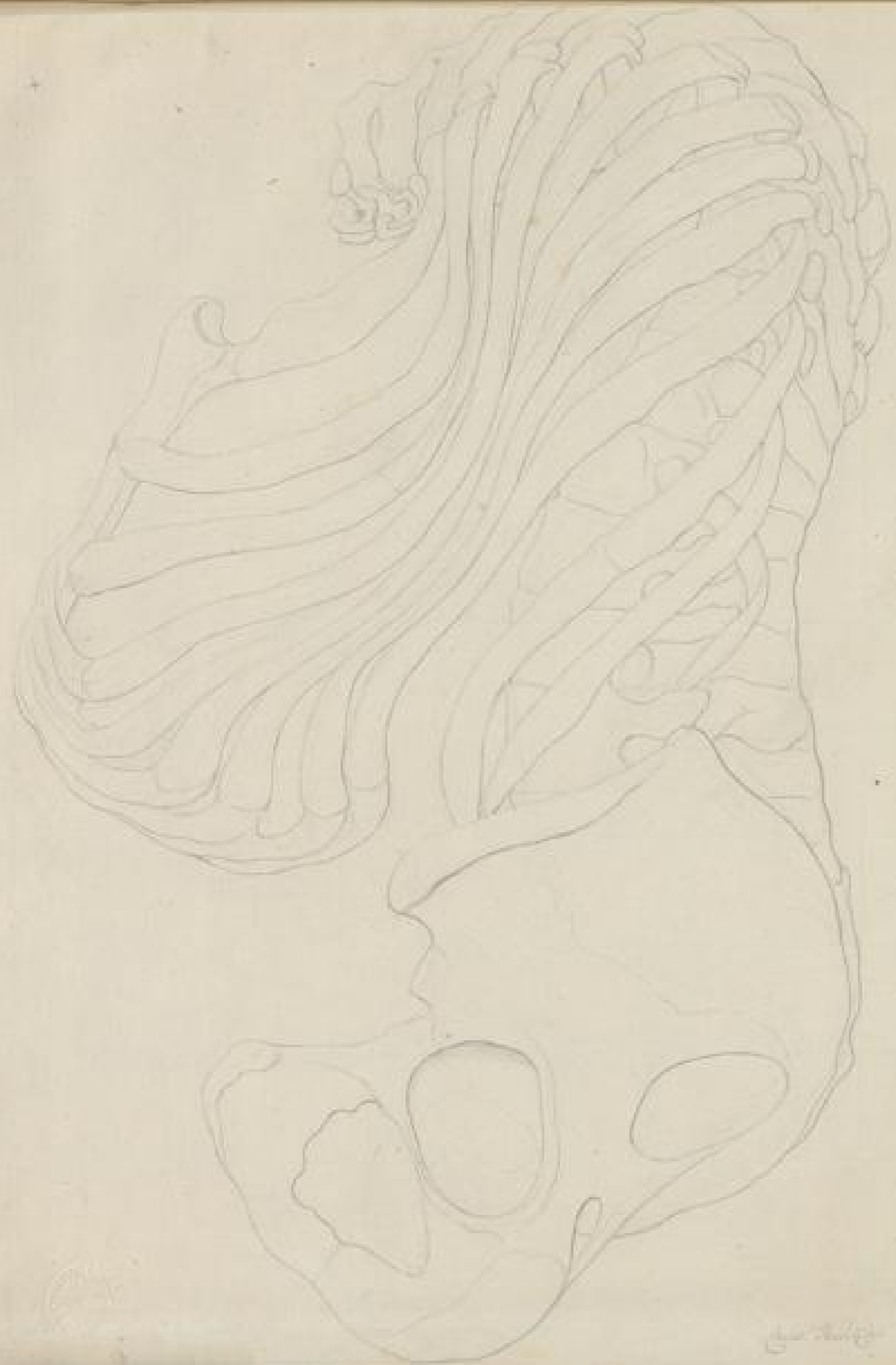60

Rhachista curvata L. *Stupa* n. n.
galeata G. n. n. *Stupa* n. n.

106



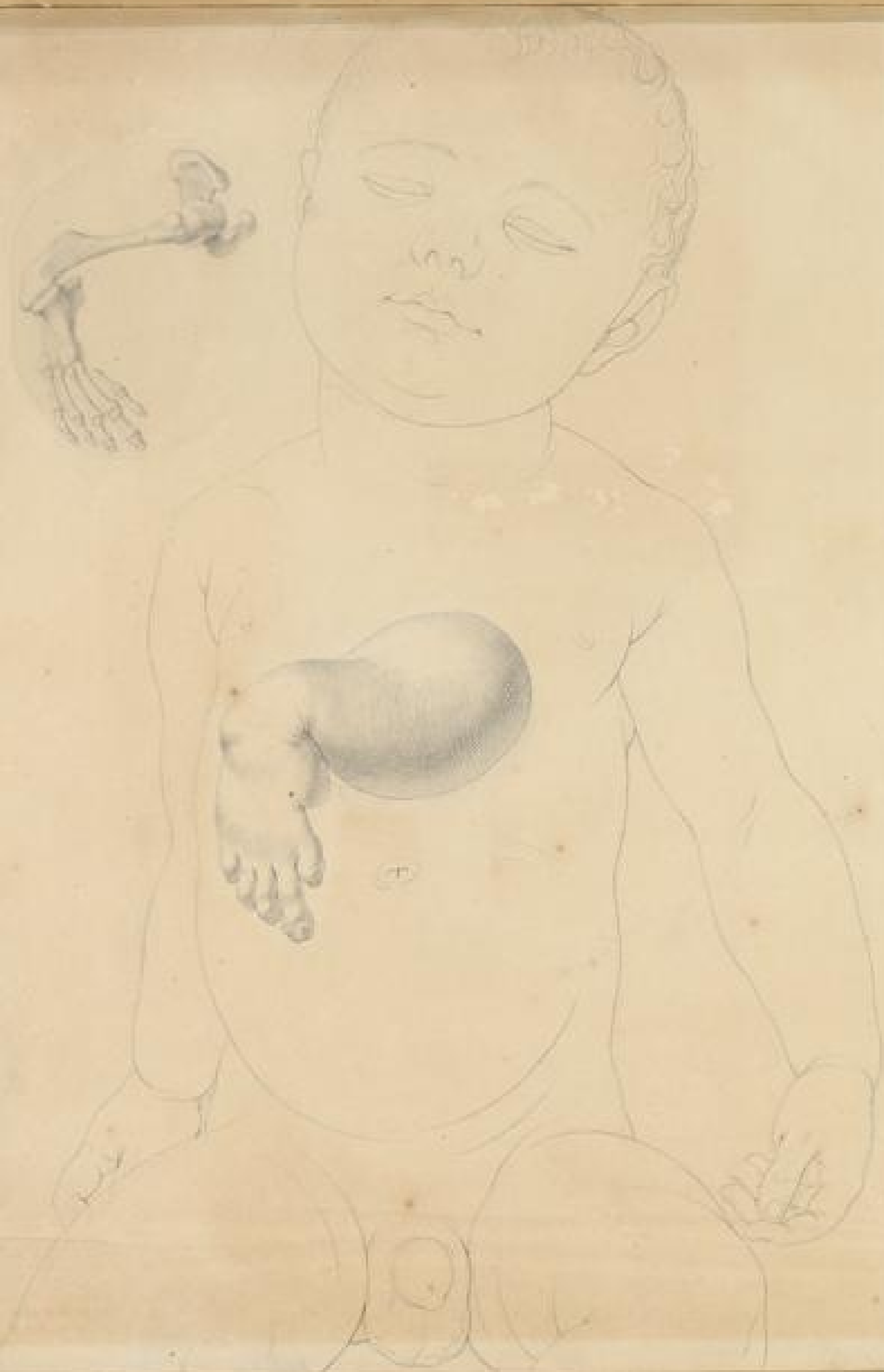78



Handwritten text, possibly a date or reference number.

Handwritten text, possibly a name or title.

Handwritten text, possibly a description or notes.



108
Hauptstadt
Frankfurt a. M.

108

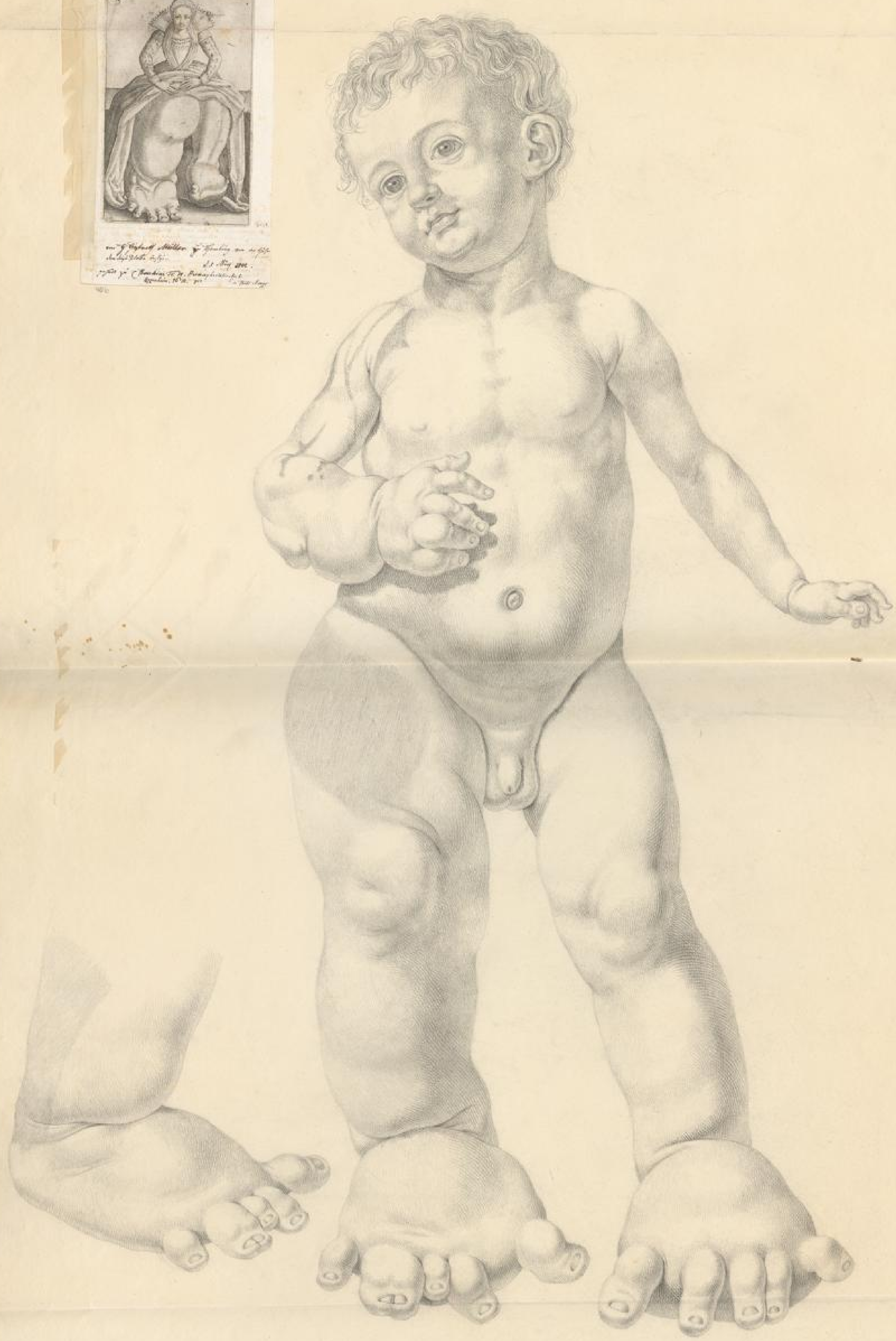108



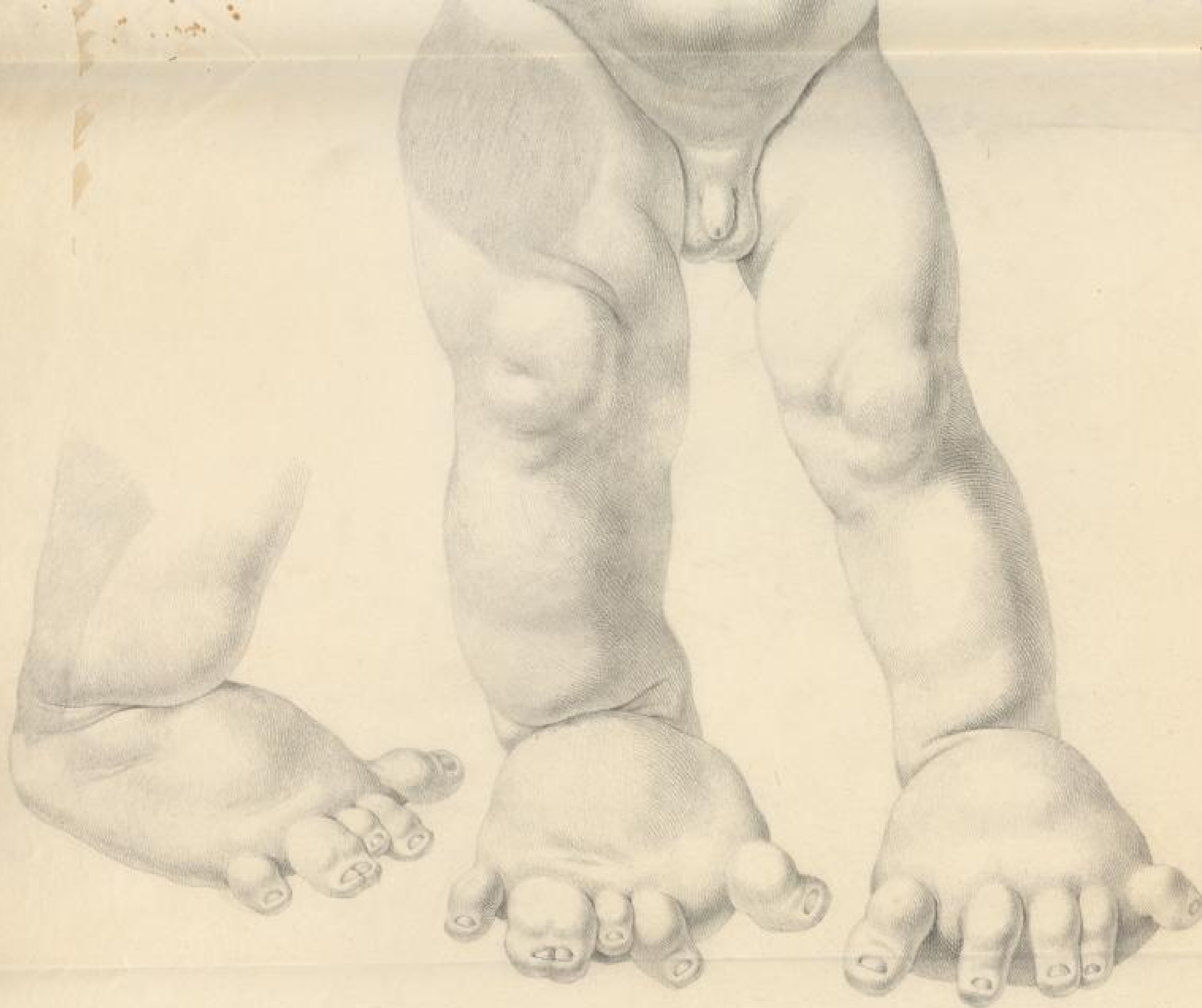
Illustration of a seated female figure, possibly a deity or allegorical figure, with a child on her lap. The figure is seated on a large, rounded base. The child is positioned in front of her, and she appears to be holding or supporting it. The figure is wearing a long, draped garment. The illustration is framed by a simple border.



Handwritten text below the small illustration, likely providing details about the figure or the source of the engraving.



Handwritten text at the bottom of the page, likely providing details about the child or the source of the engraving.



Simon Hall's anatomical engraving of the lower part of the human body, showing the legs and feet from a posterior perspective. The engraving is highly detailed, showing the musculature of the thighs, calves, and feet. The feet are positioned as if standing on a flat surface. The engraving is done in a fine-line style, typical of 18th-century medical illustrations.

